

The Myodural Bridge and Upper Cervical Care

Rethinking Assumptions About Persistent Dysfunction

By Dr. George Roth

When a patient's headache returns or an upper cervical finding persists despite repeated adjustments, we face an important question: does our explanation fit the problem? The myodural bridge complex invites chiropractors to reconsider the upper cervical region as an integrated system of bone, muscle, connective tissue and dura. It also provides a starting point for investigating approaches aimed at more durable clinical improvement.

For more than a century, chiropractors have focused on the relationship between the upper cervical spine and health. Our understanding of this region continues to evolve. As it does, our treatment assumptions must evolve with it.

Anatomy that broadens the clinical picture

The myodural bridge complex consists of connective tissue links between the suboccipital musculature, associated ligamentous structures and the spinal dura mater (Figure 1). Connections involving the rectus capitis posterior minor, rectus capitis posterior major and obliquus capitis inferior traverse the upper cervical interspaces. This anatomy places local muscular tension in direct mechanical continuity with the dura.[1]

Proposed functions include stabilizing the dura during head movement and influencing cerebrospinal fluid dynamics. A 2026 review also discusses a possible role in proprioceptive signaling and associations with several cranio-cervical disorders.[1] These possibilities expand our understanding of the region, although their clinical significance remains under investigation.

Ma and colleagues studied these connections in dogs. Electrical stimulation of the obliquus capitis inferior increased cerebrospinal fluid pressure; severing its myodural attachments eliminated that response.[2] This supports a mechanical link between muscle tone and dural function in that experimental model. It does not establish that a particular treatment improves cerebrospinal fluid circulation or neurological symptoms in humans.

For practitioners, the implication is compelling: assessment of the upper cervical region should consider the tissues connecting its joints to the dura, alongside joint position and movement.

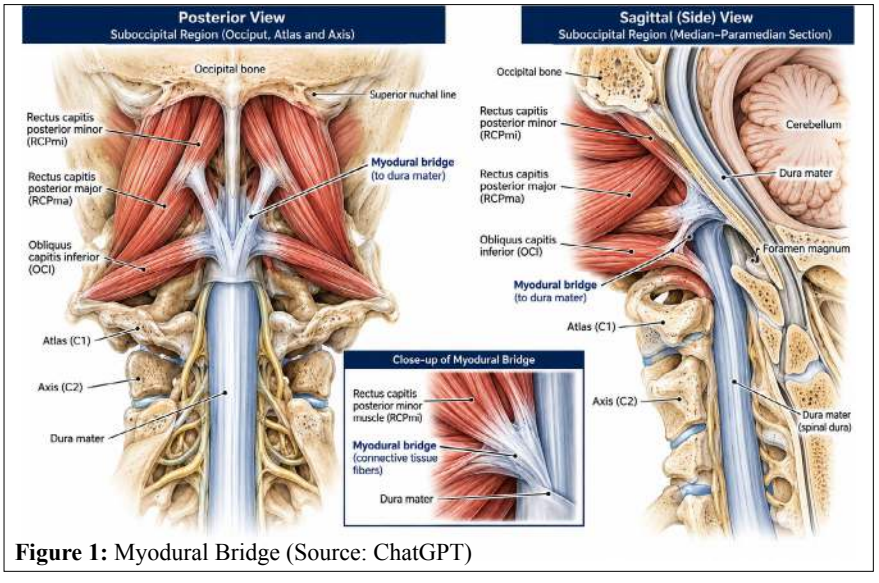

Figure 1: Myodural Bridge (Source: ChatGPT)

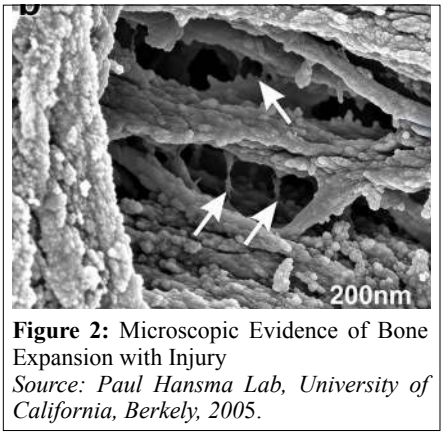

Figure 2: Microscopic Evidence of Bone Expansion with Injury
Source: Paul Hansma Lab, University of California, Berkely, 2005.

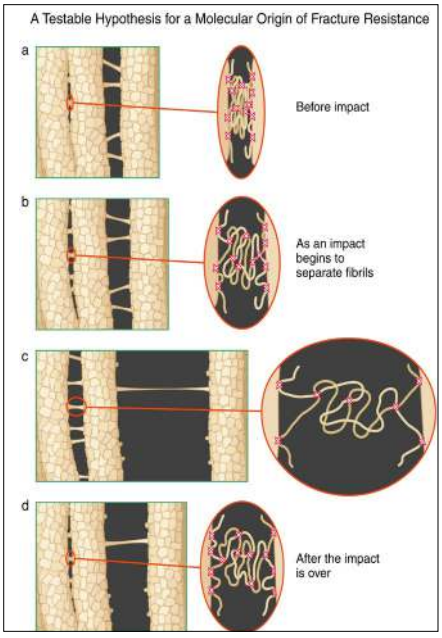

Is it articular dysfunction or osseous asymmetry?

My interest in this question began in chiropractic college, where I spent several years as an anatomy laboratory assistant. Comparing paired joints, I noticed that the bony ends of hips, knees and shoulders sometimes differed in size. The larger side often appeared to have more degenerative changes. Similar findings on radiographs led me to question whether some appar-

ent positional abnormalities might also reflect differences in bone morphology.

Published research offers relevant, though limited, support for examining bone size. Wluka and colleagues found associations between tibial plateau area and radiographic features of knee osteoarthritis[3] Fantner and colleagues demonstrated how sacrificial bonds and hidden molecular length help bone dissipate energy during fracture (Figure 2)[4] Together, these studies show that bone geometry and material behavior deserve attention, suggesting the importance of a more targeted osseous- fascial approach. [5]

In vertebral specimens I have examined, differences in the dimensions of paired structures have raised a further question: could anatomical asymmetry

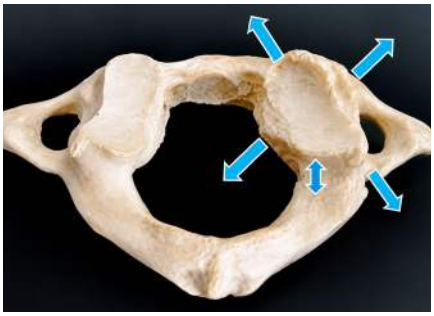

Figure 3: C1, cast from a skeletal specimen, demonstrating enlargement of the articular process on the right (2 mm in every dimension). Source: Matrix Institute

sometimes contribute to an appearance interpreted as rotation or translation? This distinction matters clinically. If an apparent articular misalignment, in fact reflects altered bone shape, repeated attempts to correct the position may fail to address the underlying structural dysfunction.

A paradigm worth testing

The model we propose considers changes in bone morphology as potential contributors to altered biomechanics within the interconnected suboccipital system. Under this model, persistent clinical findings require an explanation beyond joint malposition. Evidence from anatomical specimens clearly demonstrates variance in the relative size of articular elements, as seen in Figure 3. Relevant to the upper cervical spine, research has also demonstrated changes in bone shape and thickness of the cranium related to past impacts, which may be a factor in outcomes associated with traumatic brain injury.[6] The combination of matching osseous alterations in both the upper cervical spine and the occipital bone in particular is a common observation among practitioners trained in these methods.

Matrix Repatterning, described in my published work,[7] is a gentle, targeted approach intended to address dysfunction within the osseous and fascial framework. Based on my experience and that of my colleagues, addressing these underlying osseous changes appears to rapidly restore the stability and integrity of the myofascial elements in the suboccipital region. Using this gentle, targeted approach, we have documented significant improvement in cases of chronic headache, including migraine, as well as visual, auditory, vestibular and general autonomic (vagal dysautonomia) dysfunction.[8]

Let outcomes challenge our assumptions

Based on the recent revelations regarding the anatomy and clinical relevance of the myodural bridge and related anatomical elements relevant to TBI and cervical spine injury, I believe that prospective studies with reproducible assessments, comparison groups and meaningful follow-up, should be instituted.

As practitioners, I suggest that we begin reconsidering our models in everyday practice. When relief is short-lived or findings repeatedly recur, a reassessment of the working diagnosis and the rationale for continuing the same intervention is justified. We should also examine the broader osseous, muscular and connective tissue context, select treatment according to the patient's presentation and risk profile, and document changes in symptoms, function, and the durability of improvement.

The myodural bridge literature does not establish that upper cervical manipulation is inherently unsafe, nor does it prove that a gentler technique is more effective. It does, however, reinforce the importance of understanding the structures affected by treatment and examining our claims with the same care we bring to our patients.

I encourage colleagues to study these crucially important anatomical features, critically evaluate alternative approaches, and advocate for research that can test their proposed mechanisms. A science-based paradigm earns its place through better explanations, reproducible findings and demonstrably better outcomes. Our patients' persistent problems should keep us asking whether our current model is sufficient—and what evidence would help us improve it.

Dr. George Roth, BSc, DC, ND, CMRP is a graduate of the University of Toronto, the Canadian Memorial Chiropractic College and the Ontario College of Naturopathic Medicine. He has also studied osteopathic medicine, including an extended preceptorship at Doctors' Hospital North, Columbus, Ohio. He is the developer of Matrix Repatterning and is the Director of Education at the Matrix Institute in Toronto. He is the co-author of Positional Release Therapy (Elsevier, 1997), and the author of The Matrix Repatterning Program for Pain Relief (New Harbinger, 2005). His work is also featured in the Brain's Way of Healing, by Dr. Norman Doidge, (Penguin, 2015). The author teaches and practises Matrix Repatterning and is the author of a book describing the approach. For more information, visit: www.matrixinstitute.net and email the author at: info@matrixinstitute.net

References

1. Zhang L, Song X, Chen C, et al. The myodural bridge complex: a comprehensive review of morphology, physiology, developmental biology and pathology. Front Med. 2026.
2. Ma Y, Tang W, Gong DZ, et al. The morphology, biomechanics, and physiological function of the suboccipital myodural connections. Sci Rep. 2021.
3. Wluka AE, Wang Y, Davis SR, Cicuttini FM. Tibial plateau size is related to grade of joint space narrowing and osteophytes in healthy women and in women with osteoarthritis. Ann Rheum Dis. 2005.
4. Fantner GE, Hassenkam T, Kindt JH, et al. Sacrificial bonds and hidden length dissipate energy as mineralized fibrils separate during bone fracture. Nat Mater. 2005.
5. Roth GB. Bone Size Matters, How Bone Size May Be Affecting Clinical Outcomes. The American Chiropractor Magazine, February 2024.
6. Semple BD, Panagiotopoulou O. Cranial Bone Changes Induced by Mild Traumatic Brain Injuries: A Neglected Player in Concussion Outcomes? Neurotrauma Rep. 2023 Jun 20.
7. Roth GB. The Matrix Repatterning Program for Pain Relief. Oakland, CA: New Harbinger Publications; 2005.
8. Chase M, Roth GB. The Application of a Form of Osseous-Fascial Manipulation in the Case of a Mild Traumatic Brain Injury (mTBI) Accompanied by Dysautonomia. Preprint report; July 30, 2026.

NEW PODCAST EPISODES

Find out the latest **Tic Talk Podcasts** episodes. Tic-Talk.net.