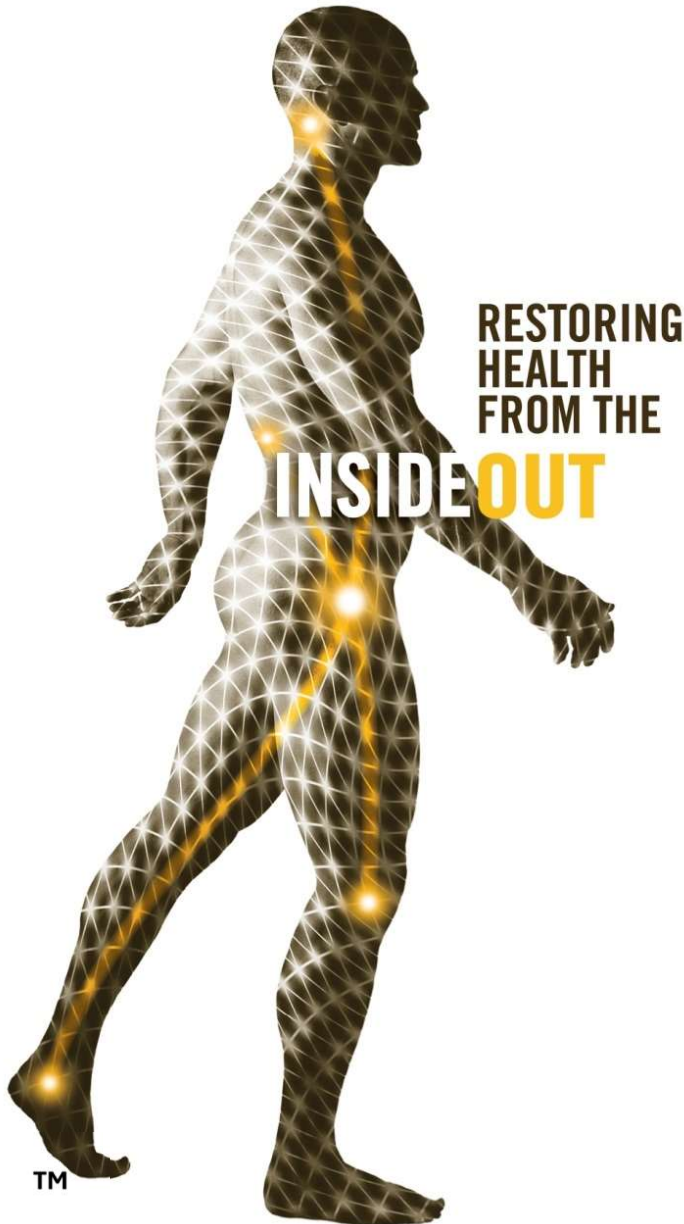




MATRIX REPATTERNING[®]
Advanced Therapeutic Solutions



Lumbar Spine, Pelvis (LP)



MATRIX INSTITUTE[™]
Empowerment Through Knowledge

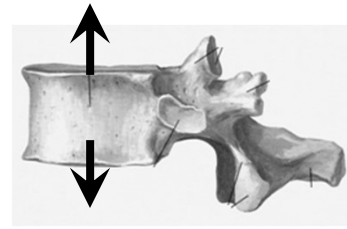
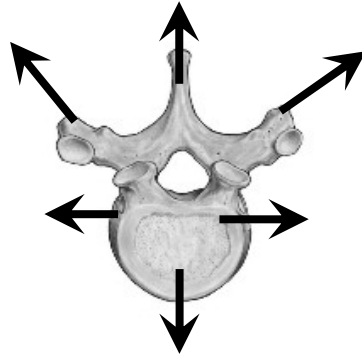
Table of Contents

Description	Page #
Lumbar Spine and Pelvis (LP)	
Lumbar Spine, Anterior & Posterior Aspects	4-7
Ilium, Ischium	8-9
Ilium	10-11
Sacral Base	12-13
Sacrum, Inferior	14-15
Pelvis, Anterior Aspect	16-17
Sacroiliac Joint	18-25
Femoral Head, Neck, and Anterior Acetabulum	26-27
Femoral Head, Neck, and Anterior Acetabulum with External Rotation	28-29
Femoral Head and Anterior & Posterior Acetabulum	30-31
Coccyx	32-33
Pubis	34-35
Ischial Tuberosity	36-37

Lumbar Spine, Anterior & Posterior Aspects

LP
L1-5

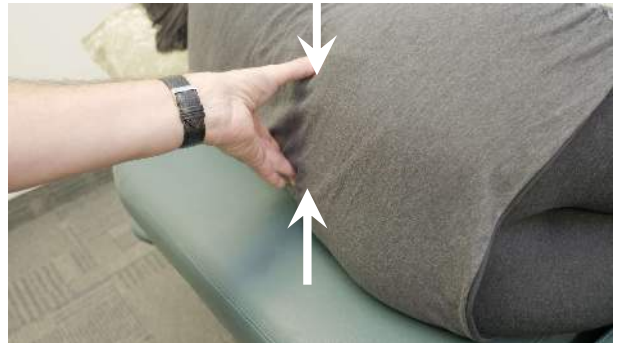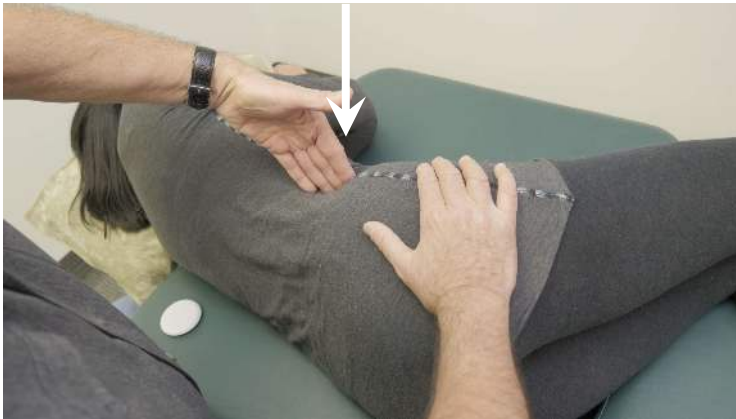LESION: Lumbar Spine, X / Y / Z Axis Expansion



TEST: X Axis, anterior and posterior aspect

Contact: Lateral lower trunk

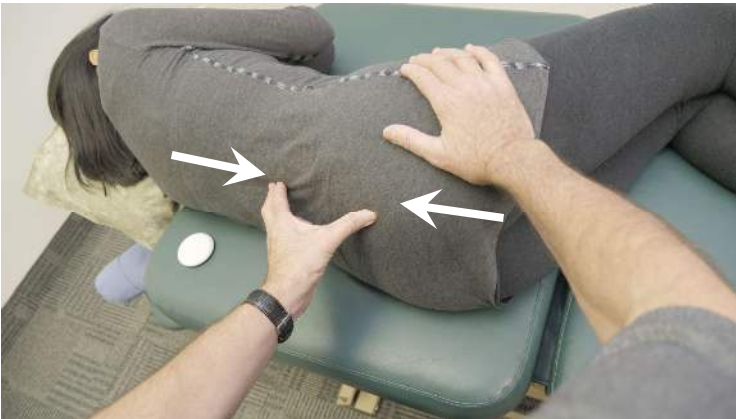
Containment: Medial



TEST: Y Axis

Contacts: Spinal sulcus longitudinally, at level of involvement

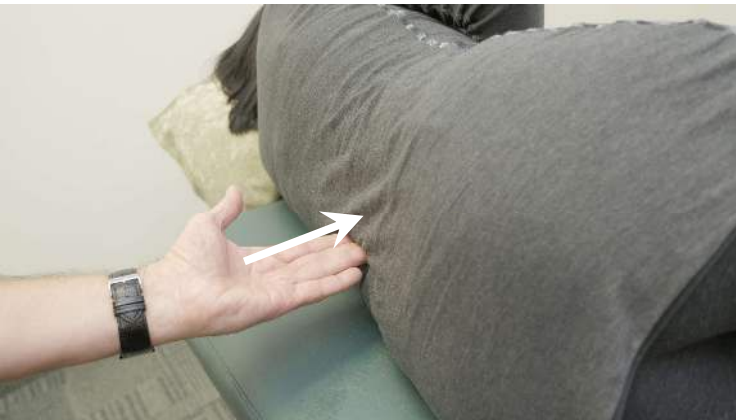Containment: Superior & inferior



TEST: Z Axis

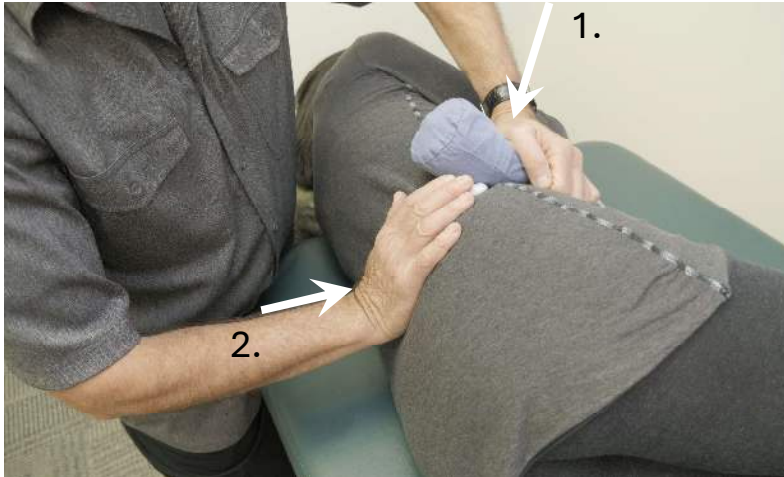
Contacts: Spinous processes at level of involvement

Containment: Anterior



Lumbar Spine, Anterior Aspect

LP
L1-5



TREATMENT: X / Z Axis Combined

Client Position: Lateral recumbent, involved side up

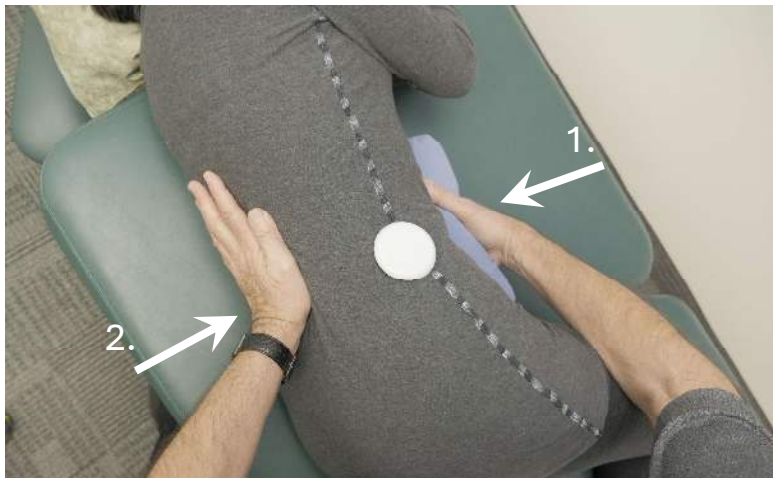
Practitioner Position: Side of table, facing client's feet

Contacts:

1. Lateral trunk just superior to iliac crest
2. Posterior spinous process

Containment:

1. Medial & inferior
2. Anterior



TREATMENT: Z Axis

Client Position: Lateral recumbent, involved side up

Practitioner Position: Side of table, facing client's head

Contacts:

1. Anterior abdomen just superior to pubic symphysis
2. Posterior spinous process

Containment:

1. Posterior
2. Anterior

Lumbar Spine, Anterior Aspect

LP

L1-5

TREATMENT: X / Y Axis Combined

Client Position: Lateral recumbent, involved side up

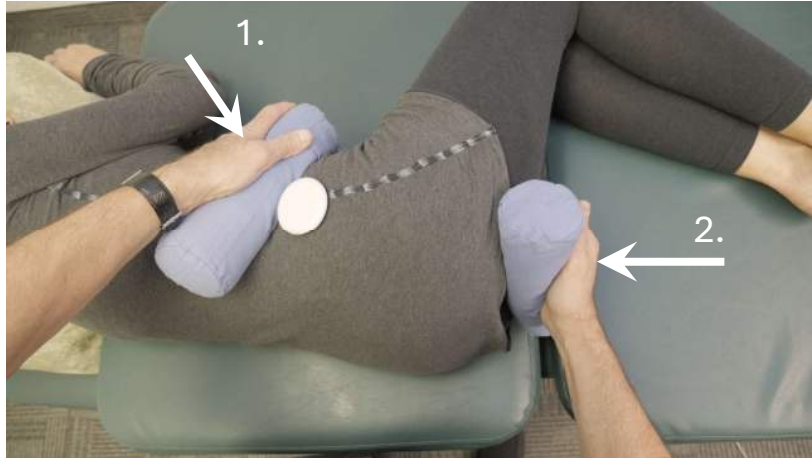
Practitioner Position: Side of table, facing client's back

Contacts:

1. Lateral rib cage at or just superior the the level of involvement
2. Inferior pelvis, just anterior to the ischial tuberosities

Containment:

1. Medial
2. Superior



TREATMENT: X / Y / Z Axis Combined

Client Position: Lateral recumbent, involved side up

Practitioner Position: Side of table, facing back of client's body

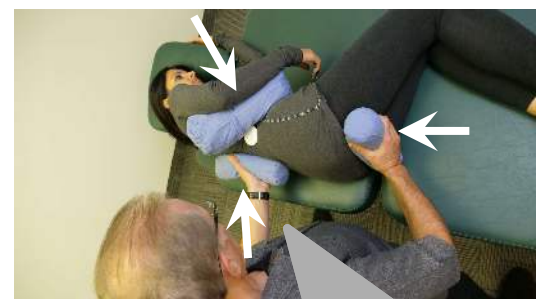
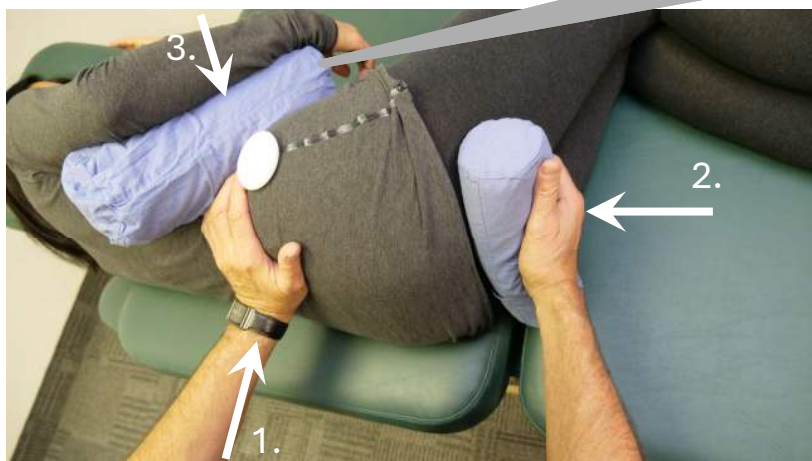
Contacts:

1. Spinous processes at level of involvement
2. Inferior pelvis, just anterior to the ischial tuberosities
3. Optional: Lateral trunk at or just superior the the level of involvement

Containment:

1. Anterior
2. Superior
3. Medial & inferior

Optional: Client can support bolster on lateral trunk assist in containment



Optional use of bolster when contacting spinous processes

Lumbar Spine, Posterior Aspect

LP
L1-5

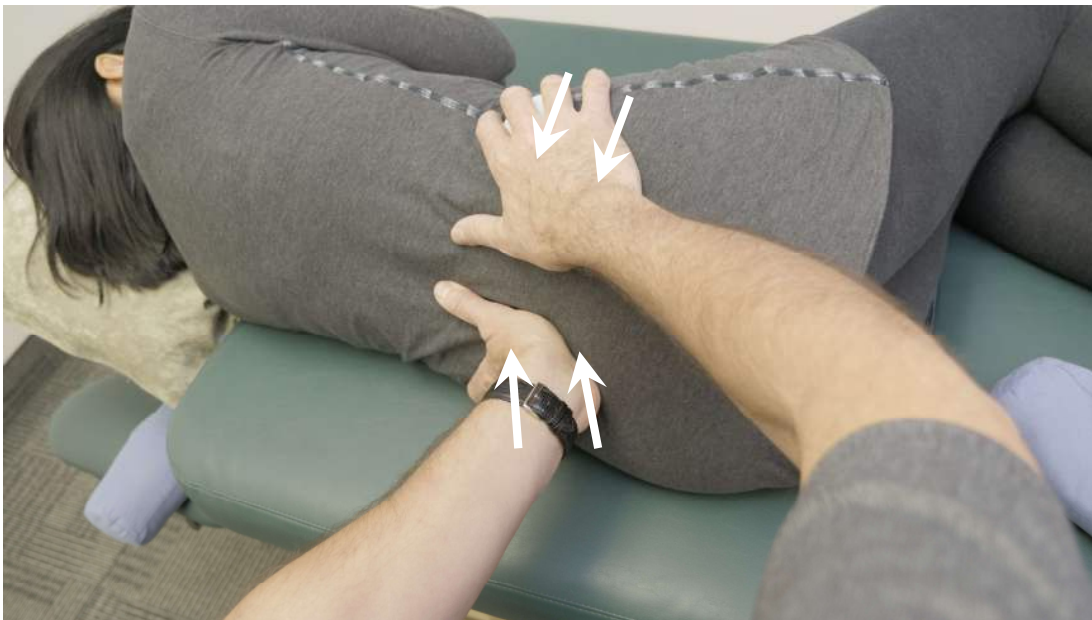TREATMENT: X Axis

Client Position: Lateral recumbent, involved side up

Practitioner Position: Side of table, facing towards client's head

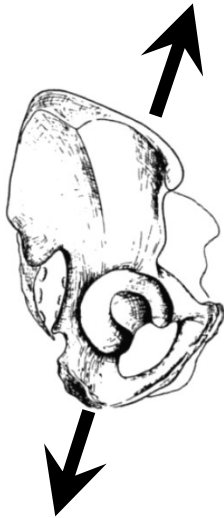Contacts: Lateral transverse processes including posterior rib angles bilaterally

Containment: Anterior and medial



Ilium, Ischium

LESION: Ilium & Ischium, Y Axis Expansion



TEST: Y Axis

Contacts: Lateral aspect of pelvis, oriented toward the Iliac tubercle and Ischial tuberosity

Containment: Inferior and superior



Ilium, Ischium

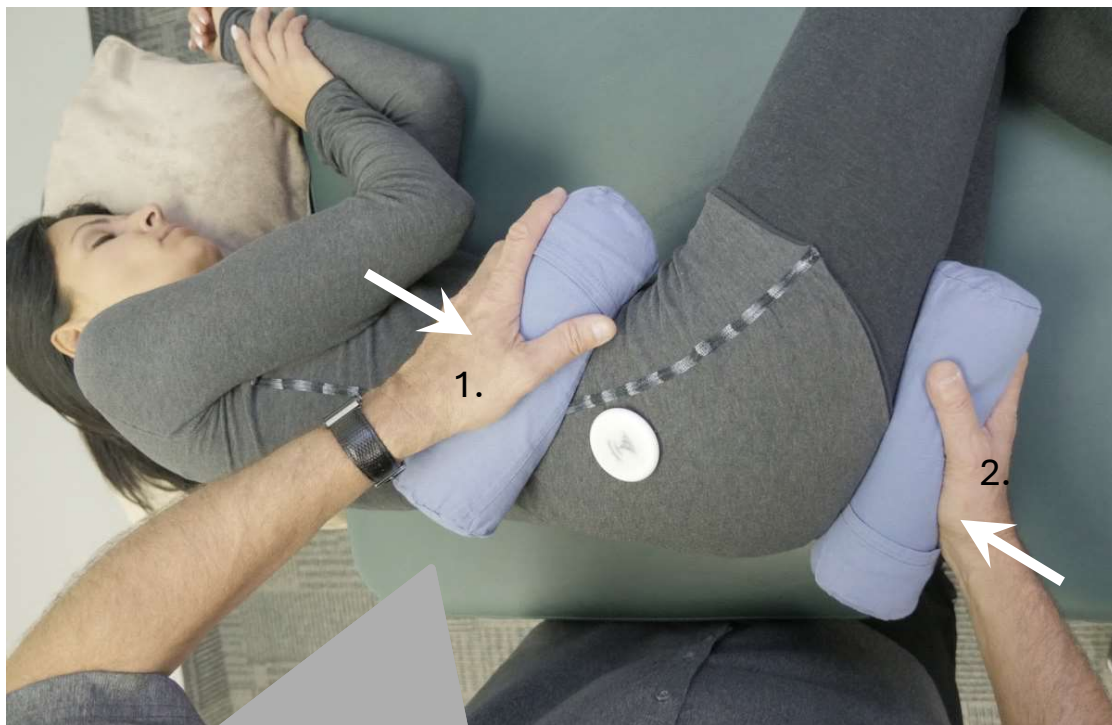
TREATMENT: Y Axis

Client Position: Lateral recumbent, involved side up

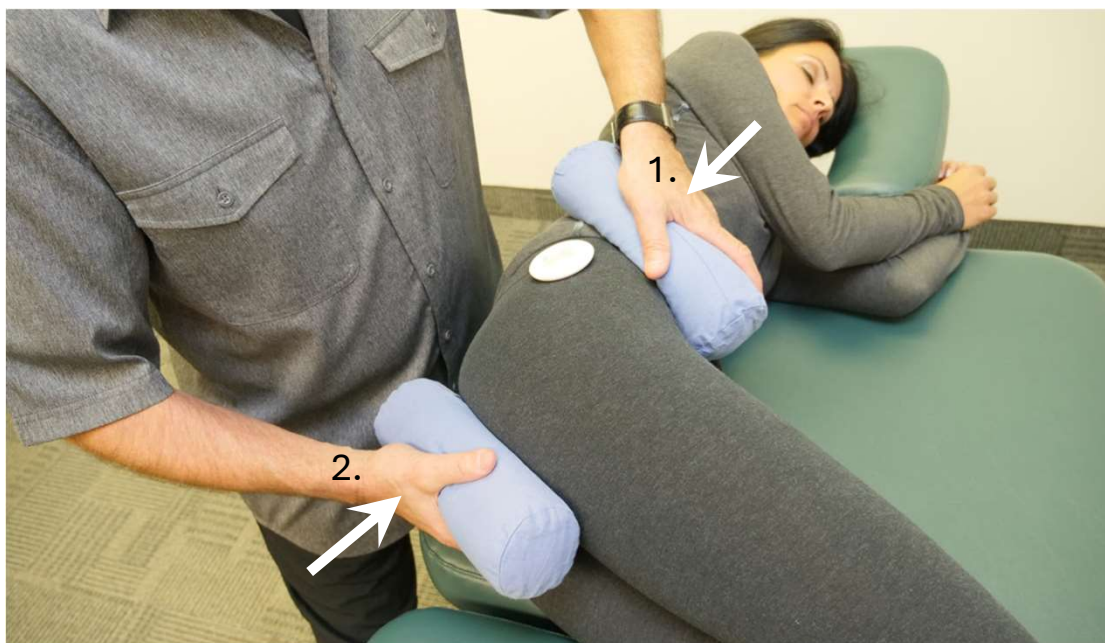
Practitioner Position: Side of table, facing back of client's body

Contacts: 1. Iliac crest, including iliac tubercle & ASIS 2. Ischial tuberosity

Containment: 1. Posterior, inferior and medial 2. Superior

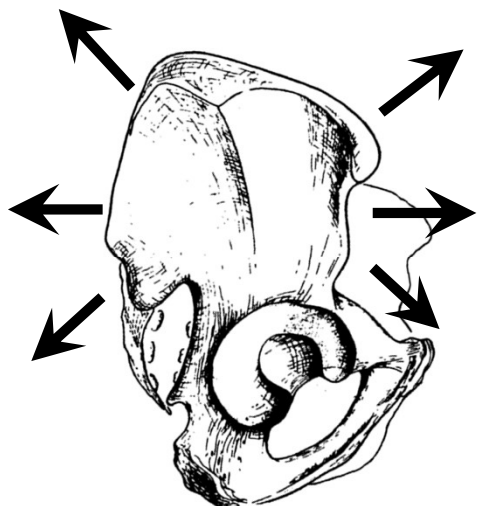


Be sure to place the superior bolster contact so it is bisected by the iliac crest, iliac tubercle and ASIS



Ilium

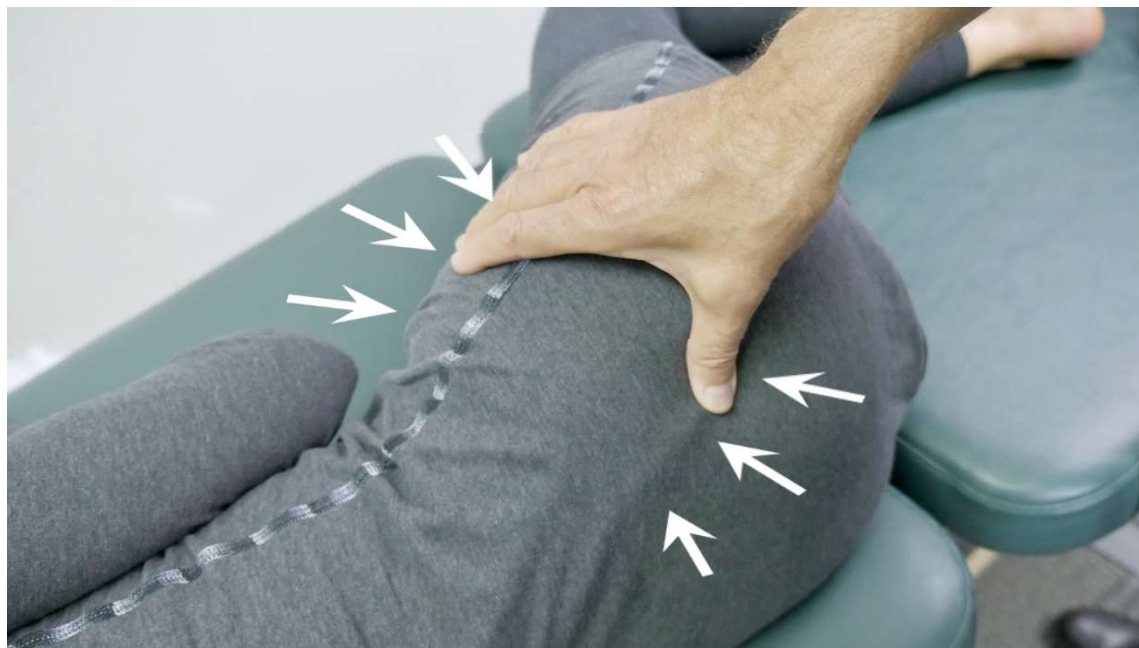LESION: Ilium, Z Axis Expansion



TEST: Z Axis

Contacts: Anterior and posterior aspects of the lateral pelvis, oriented toward the ASIS, AIIS & PSIS, PIIS (various vectors)

Containment: Posterior and anterior on various contacts, based on indicator response



Ilium

TREATMENT: Z Axis

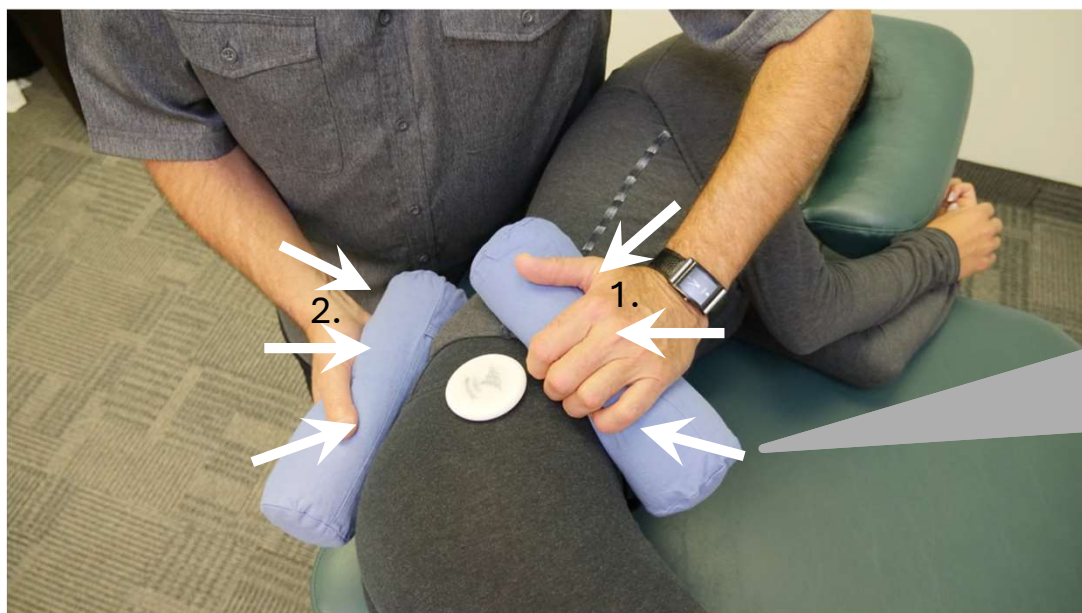
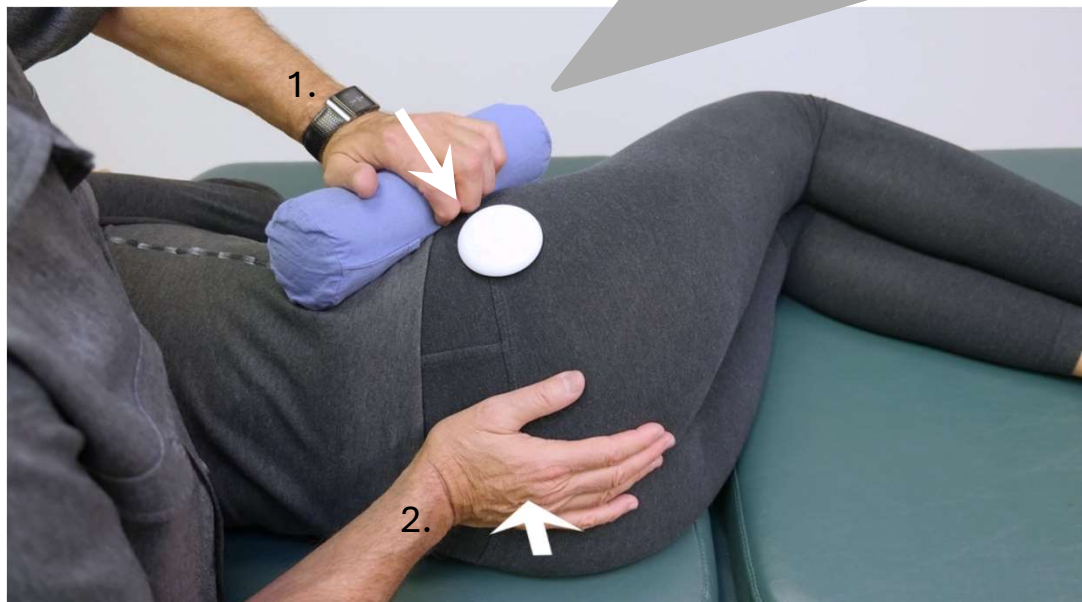Client Position: Lateral recumbent, involved side up

Practitioner Position: Side of table, facing client's feet

Contacts: 1. Iliac tubercle, ASIS, AIIS 2. PSIS, PIIS

Containment: 1. Posterior, inferior and medial 2. Anterior

Be sure to place this bolster so it is bisected by the iliac tubercle, ASIS & AIIS. Posterior contact can be with a hand or bolster, based on comfort.



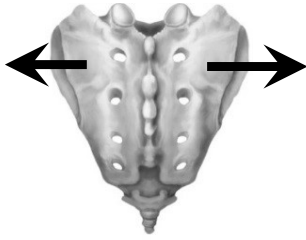
Remember to contain the various vectors based on testing.

Sacral Base

LP
SAC

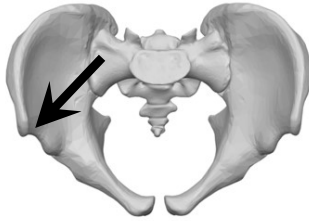
LESION:

Sacral base,
X Axis
Expansion



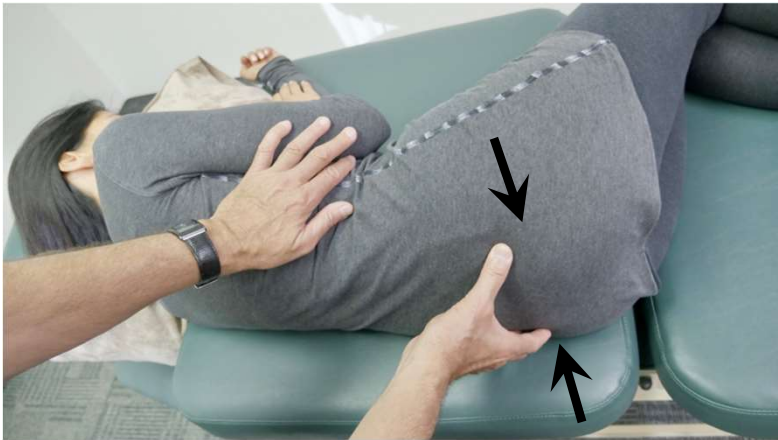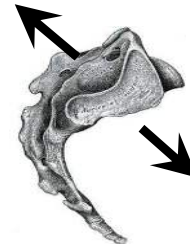
LESION:

Sacral base, X / Z
Axis Expansion



LESION:

Sacral base, Z
Axis Expansion



TEST: X Axis

Contact: Lateral aspect of PSIS bilaterally

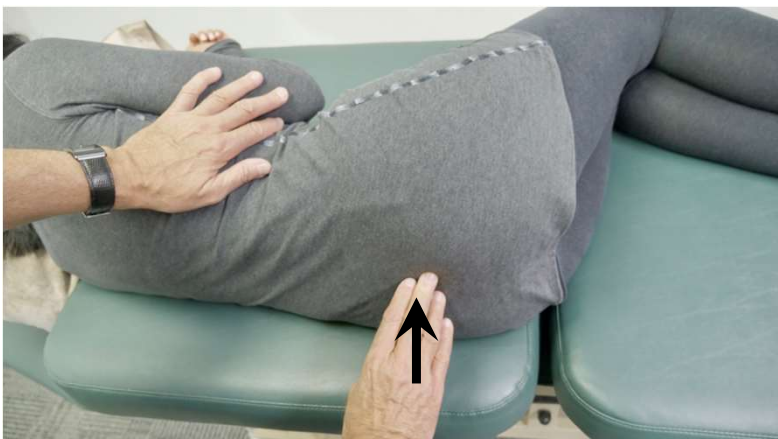Containment: Medial



TEST: X, Z Axis

Contact: Anterior and superior iliac crest

Containment: Posterior, inferior and medial



TEST: Z Axis

Contact: Sacral tubercles 1-3

Containment: Anterior

Sacral Base

TREATMENT: X / Z Axis Combined

Client Position: Lateral recumbent, involved side up

Practitioner Position: Side of table, facing client's feet

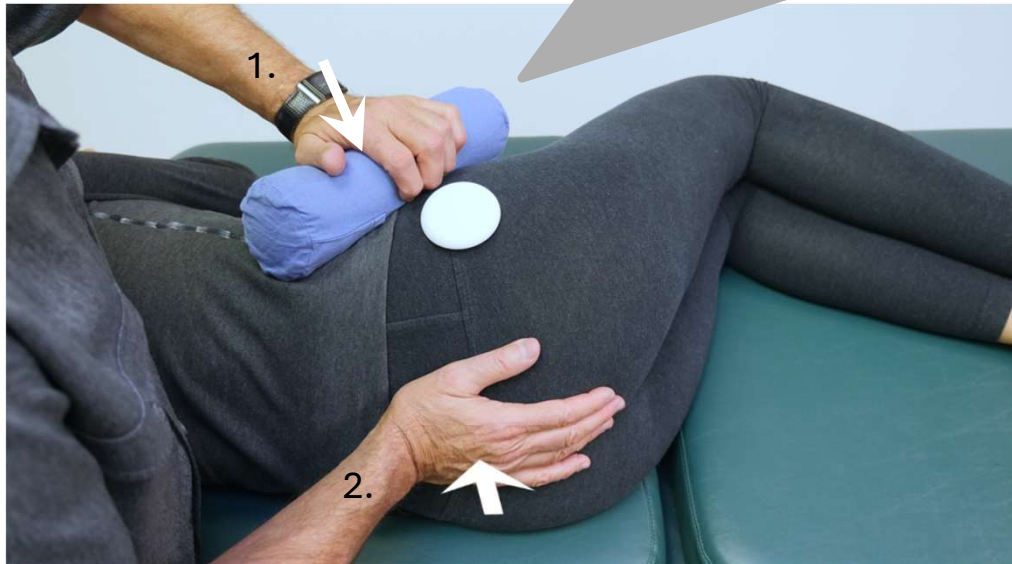
Contacts:

1. Iliac tubercle, ASIS and AILS
2. Posterior sacral tubercles at level of S1-3

Containment:

1. Posterior, inferior and medial
2. Anterior

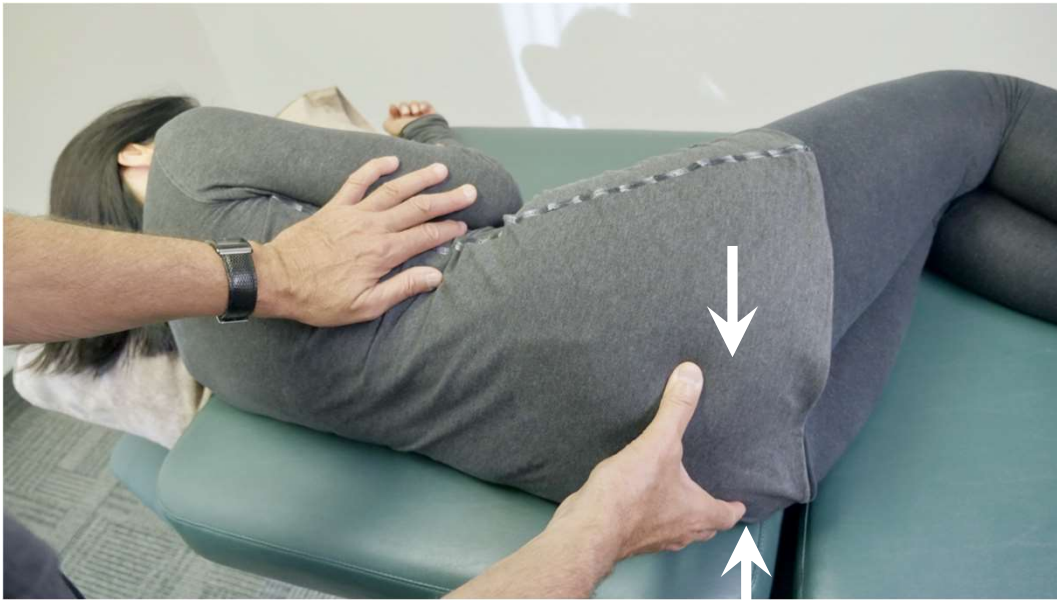
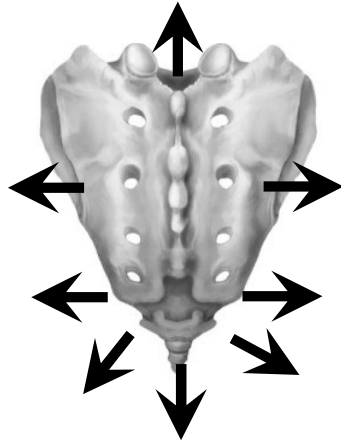
Be sure to place this bolster so it is bisected by the iliac tubercle, ASIS & AILS. Posterior contact can be with a hand or bolster, based on comfort.



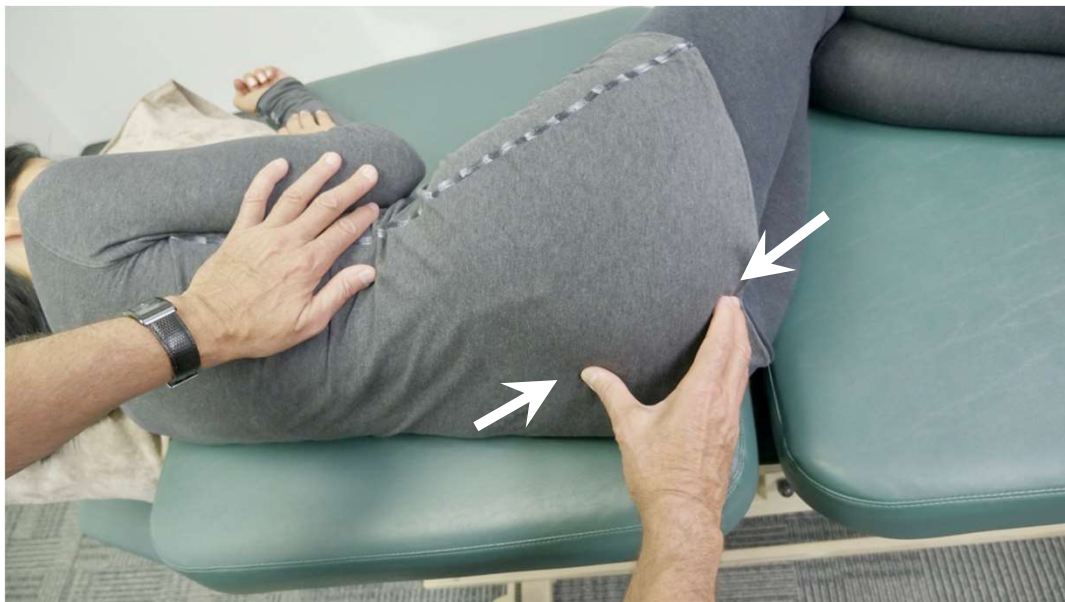Sacrum, Inferior

LP
SAC

LESION:
Sacrum, X / Y
Axis Expansion



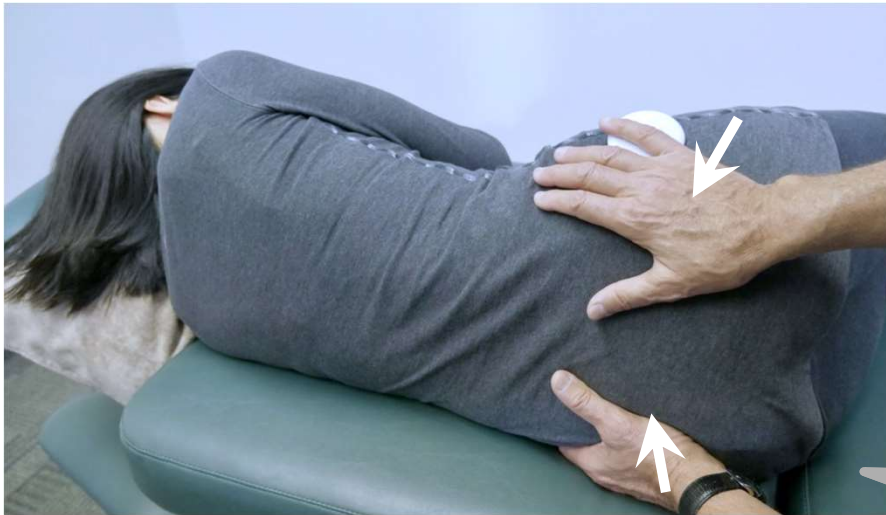TEST: X Axis
Contact: Lateral aspect of inferior portion of sacrum
Containment: Medial



TEST: Y Axis
Contact: Inferior and superior sacrum
Containment: Superior and inferior

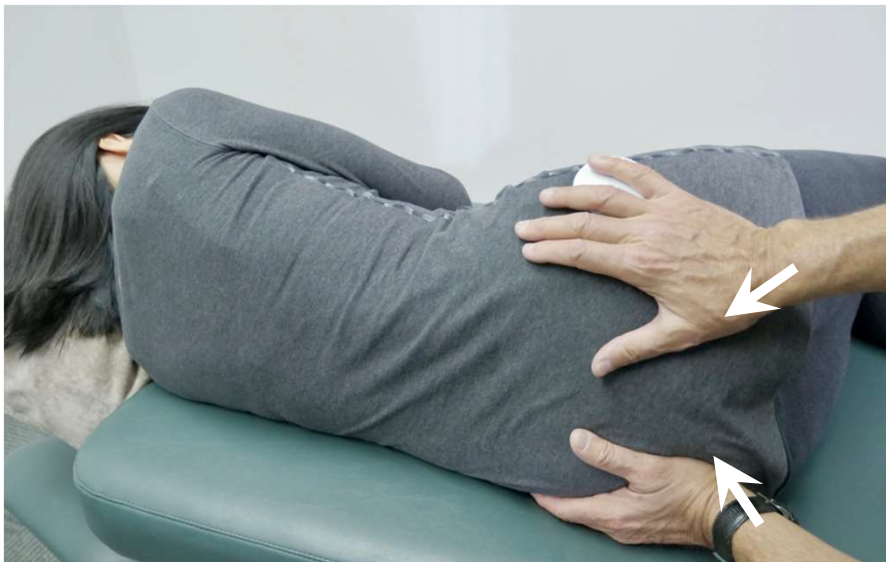Sacrum, Inferior

LP
SAC

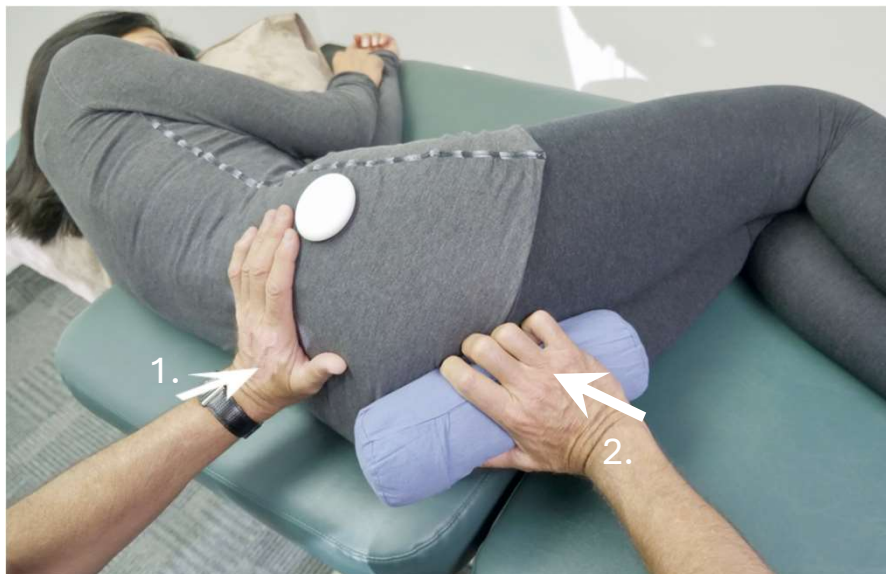

TREATMENT: X Axis
Client Position: Lateral recumbent, involved side up
Practitioner Position: Side of table, facing client's head
Contacts: Lateral sacrum bilaterally
Containment: Medial and superior, progressing from superior to inferior

1st Hand Placement
Begin treatment on superior lateral sacrum



2nd Hand Placement
Move from superior lateral sacrum to inferior lateral sacrum

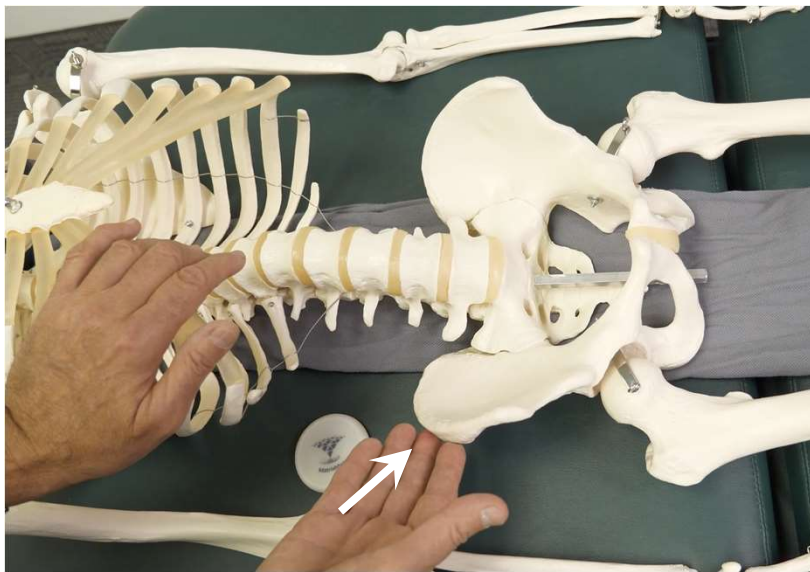
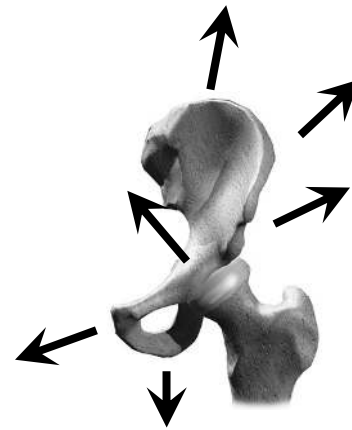
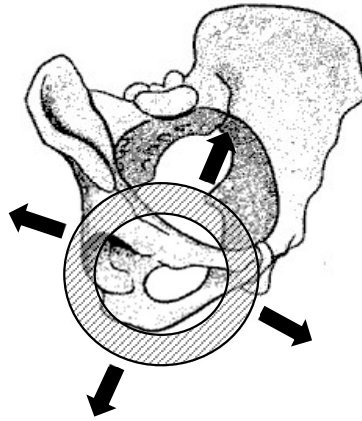


TREATMENT: Y Axis
Client Position: Lateral recumbent, involved side up
Practitioner Position: Side of table, facing client's head
Contacts:
1. Sacral base
2. Sacral apex with bolster
Containment:
1. Inferior
2. Superior

Pelvis, Anterior Aspect

LP
ANT PEL

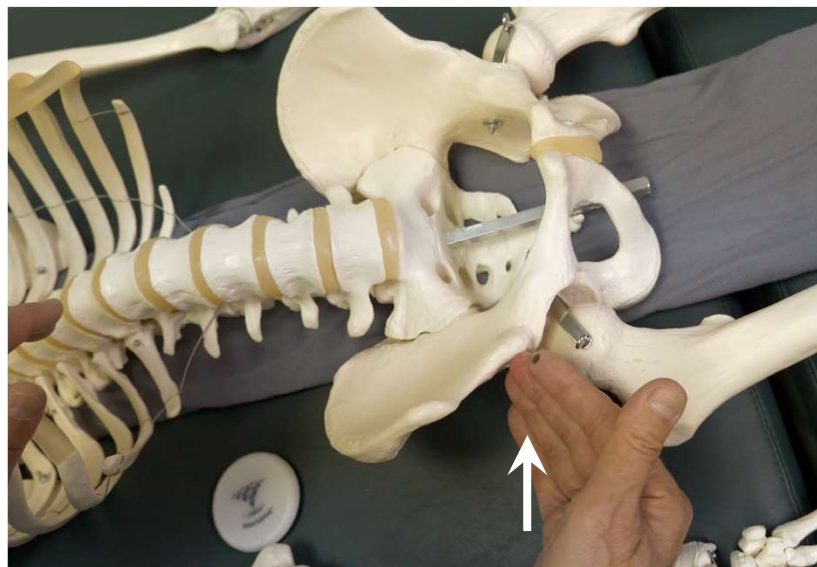LESION: Anterior Pelvis, X / Y Axis Expansion



TEST: X / Y Axis

Contact: Lateral aspects of ASIS

Containment: Medial inferior and posteriorly



TEST: X Axis

Contacts: Lateral aspect of AIIS and anterior aspect of pubic bone

Containment: Medial

Pelvis, Anterior Aspect

LP
ANT PEL

TREATMENT: X / Y Axis

Client Position: Supine

Practitioner Position: Side of table, facing client's head

Contacts:

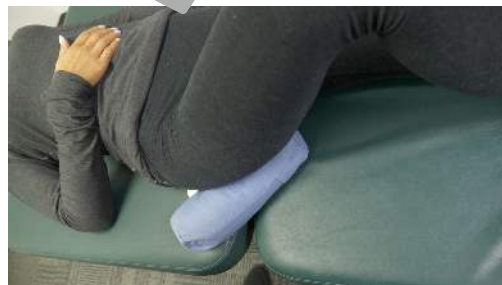1. Lateral aspects of iliac crest & ASIS for first position, then AIIS & pubic bone for second position.
2. Anterior aspect of pubic bone

Containment:

1. Medial, posterior and inferior
2. Inferior and lateral

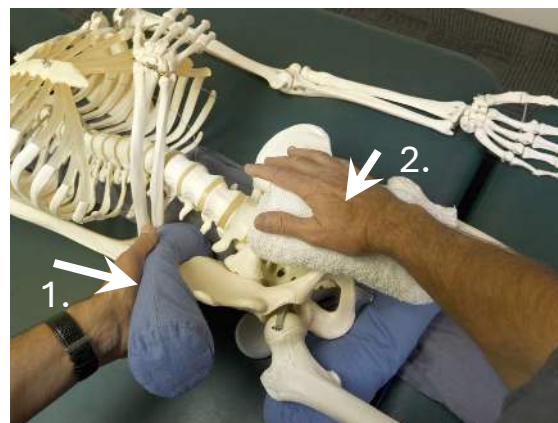
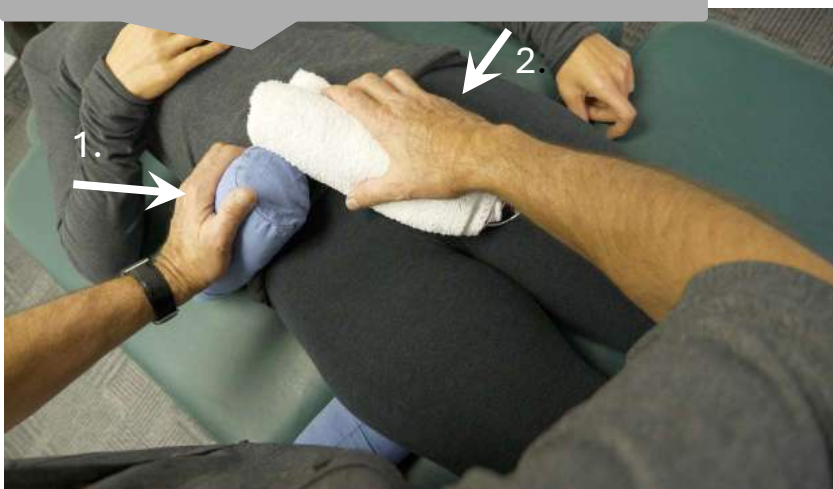Place Bolster First

Have client flex hip and knee. Lock the bolster under their ischial tuberosity. The client can then straighten their leg down onto the table. Support posterior knee with bolster for comfort.



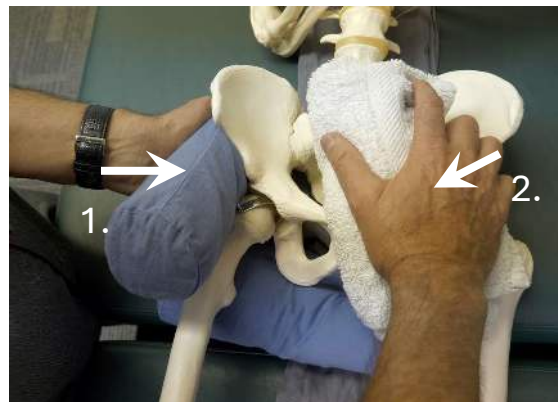
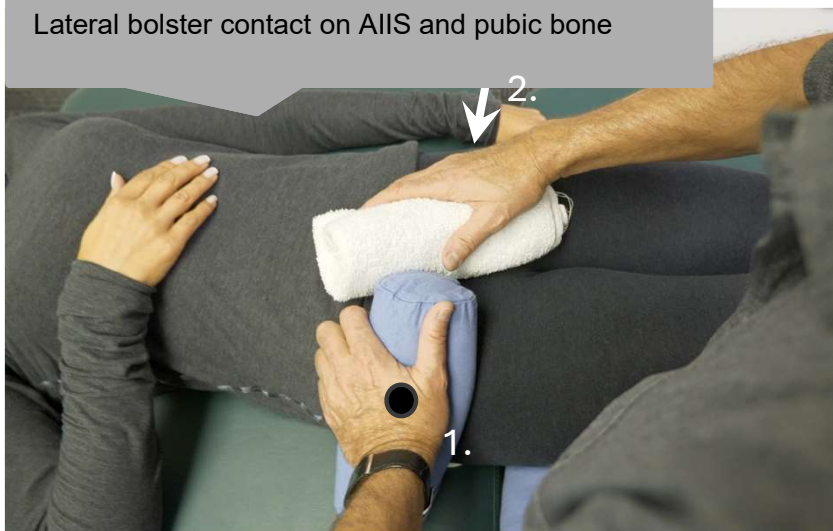
1st Hand Placement

Lateral bolster contact on iliac crest and ASIS



2nd Hand Placement

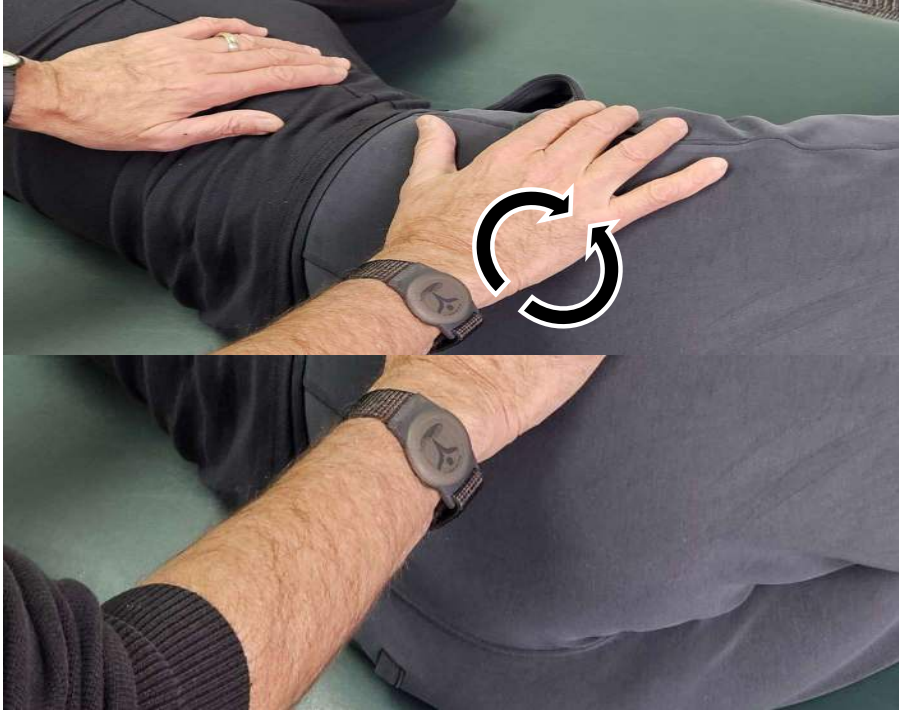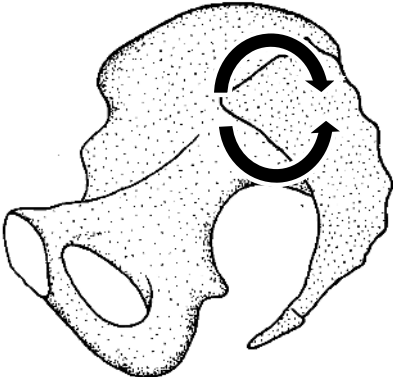
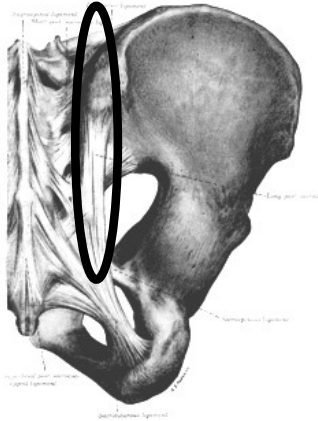
Lateral bolster contact on AIIS and pubic bone



Sacroiliac Joint

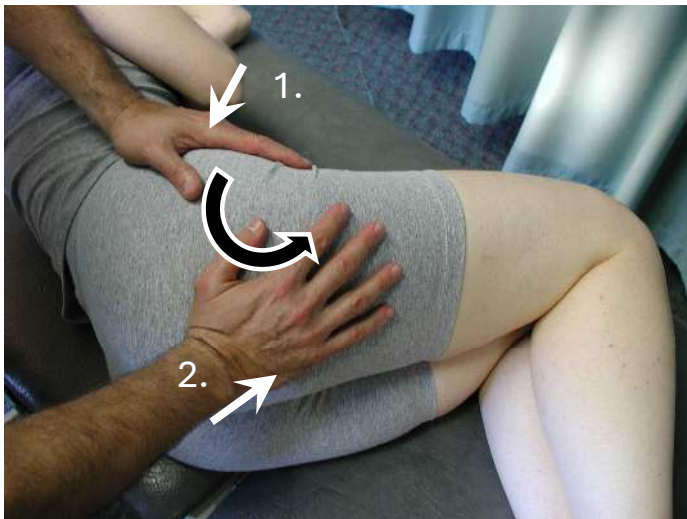
LP
SI-XR

LESION: XR +, -
(X axis rotation,
positive, negative)



TEST: X Rotation
Contact: Lateral aspect
of ilium
Containment: Medial,
Rotation in X-axis (+, -)

Sacroiliac Joint



TREATMENT: +XR

Client Position: Lateral recumbent, involved side up

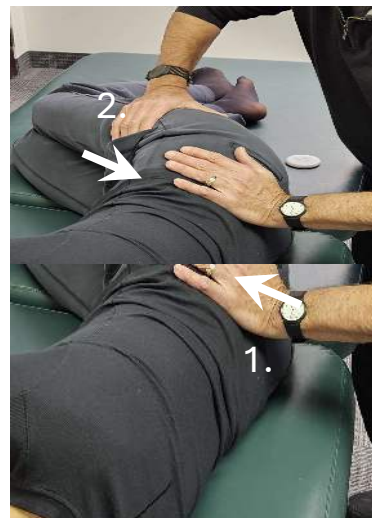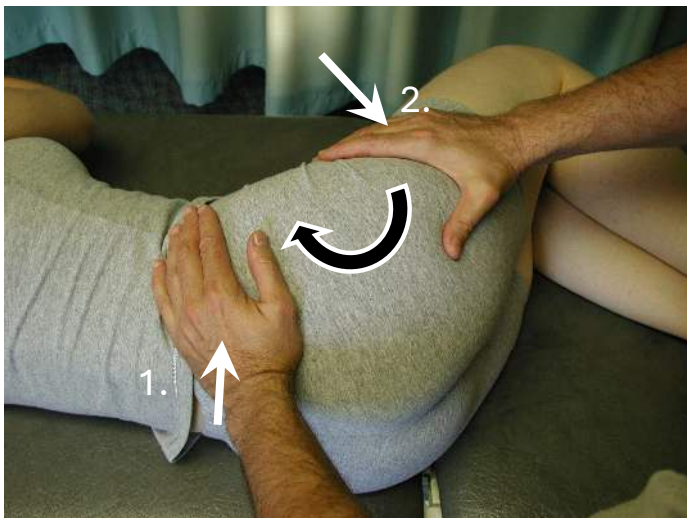
Practitioner Position: Side of table, behind patient

Contacts:

- 1. Anterior iliac crest, ASIS
- 2. Posterior ischial tuberosity

Containment:

- 1. Posterior
- 2. Anterior



TREATMENT: -XR

Client Position: Lateral recumbent, involved side up

Practitioner Position: Side of table, behind patient

Contacts:

- 1. PSIS
- 2. Anterior proximal femur

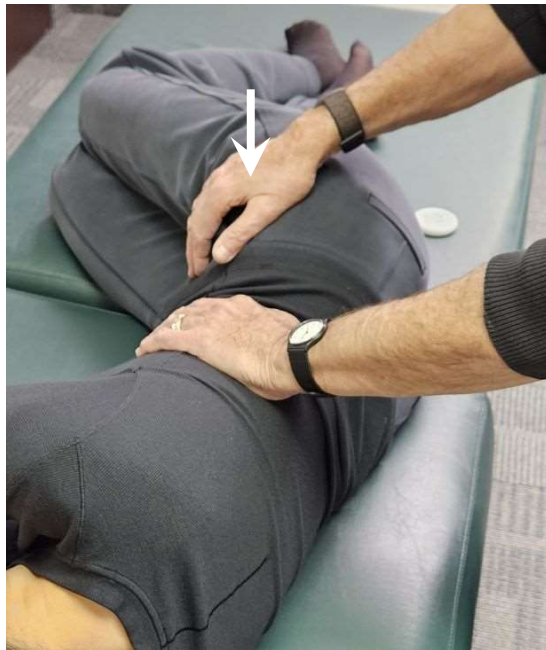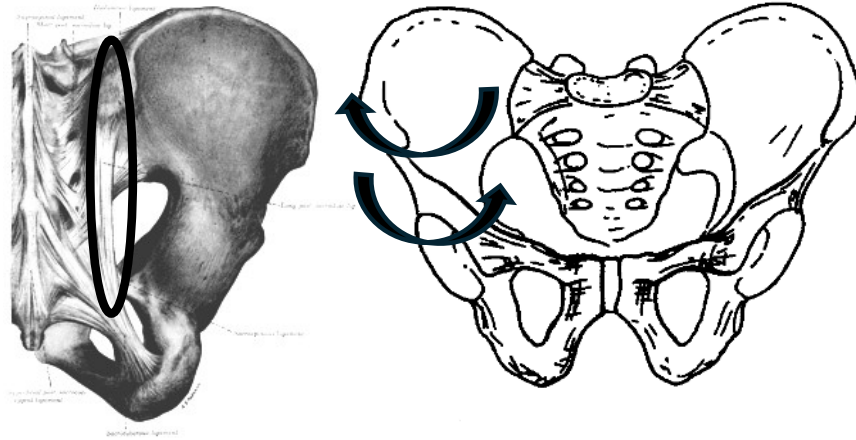
Containment:

- 1. Anterior
- 2. Posterior

Sacroiliac Joint

LP
SI-YR

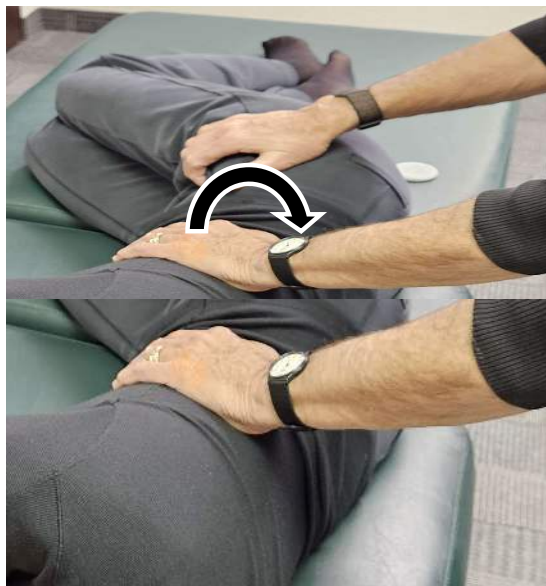LESION: YR +, -
(Y axis rotation,
positive, negative)



TEST: +Y Rotation

Contact: Anterior,
Lateral aspect of ilium

Containment: Medial

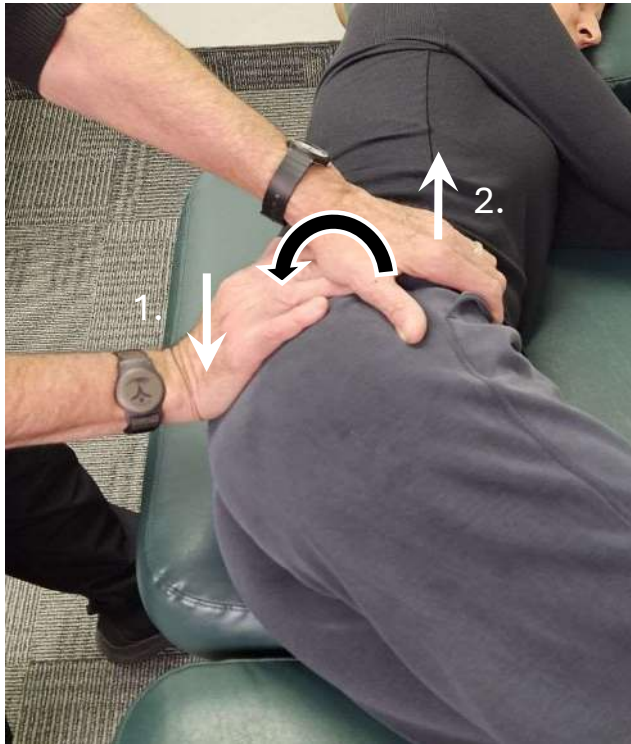

TEST: -Y Rotation

Contact: Anterior,
Medial aspect of ilium

Containment: Lateral
with fingers, with palm
of hand acting as a
fulcrum on lateral
aspect of ilium

Sacroiliac Joint



TREATMENT: +YR

Client Position: Lateral recumbent, involved side up

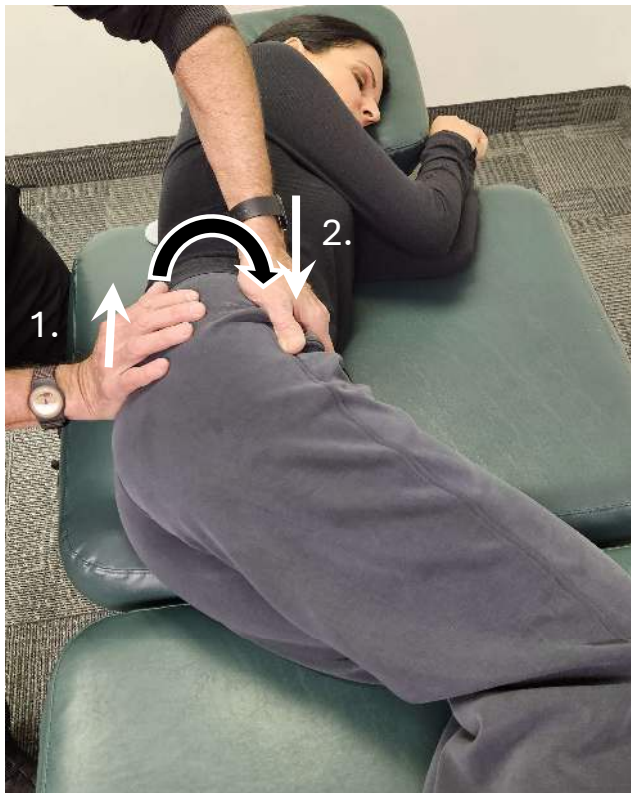Practitioner Position: Side of table, behind patient

Contacts:

1. Lateral aspect of PSIS
2. Medial, anterior aspect of iliac crest

Containment:

1. Medial
2. Lateral



TREATMENT: -YR

Client Position: Lateral recumbent, involved side up

Practitioner Position: Side of table, behind patient

Contacts:

1. Medial aspect of PSIS
2. Anterior, lateral aspect of iliac crest

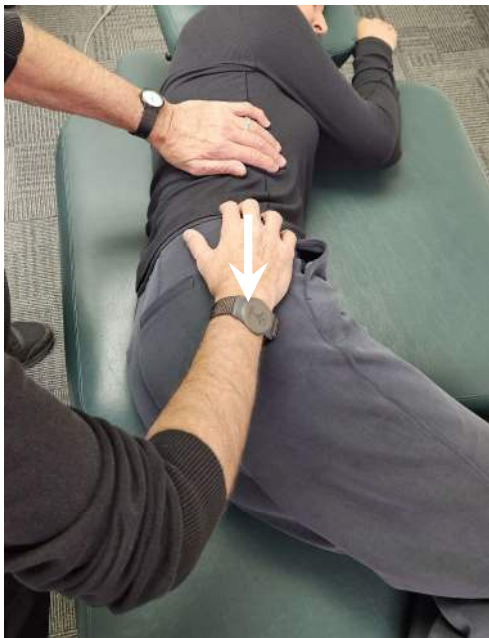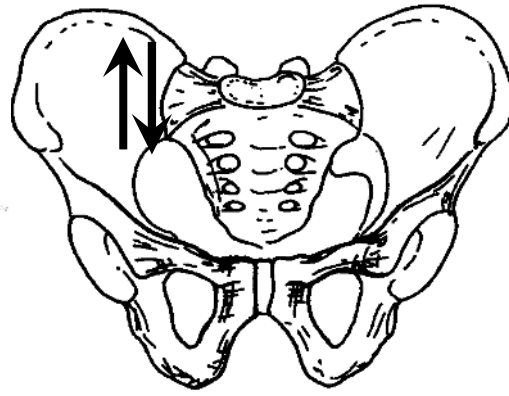
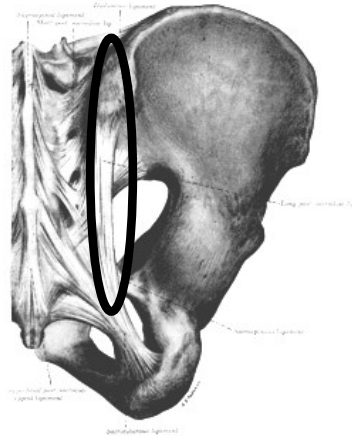
Containment:

1. Lateral
2. Medial

Sacroiliac Joint

LP
SI-YT

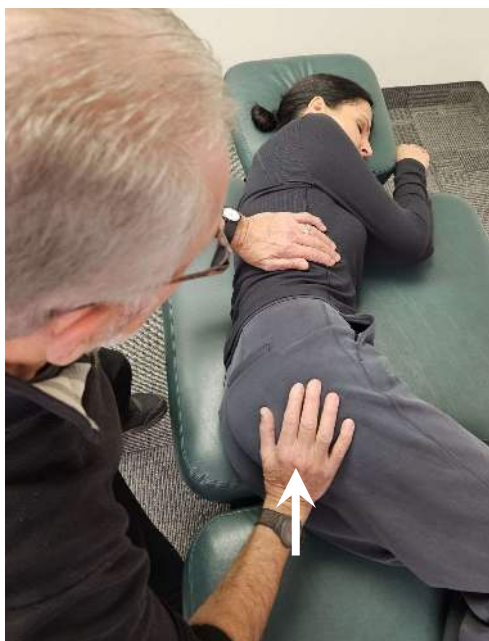LESION: YT +, -
(Y axis translation,
positive, negative)



TEST: +Y Translation

Contact: Superior aspect of ilium

Containment: Inferior



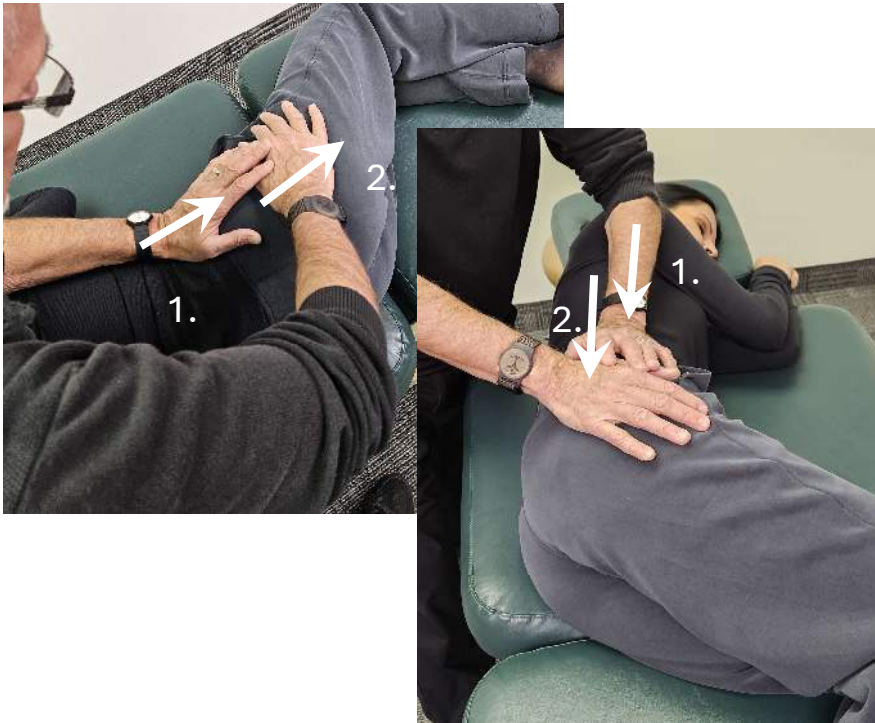TEST: -Y Translation

Contact: Inferior aspect of ischial tuberosity

Containment: Superior

Sacroiliac Joint

LP
SI-YT



TREATMENT: +YT

Client Position: Lateral recumbent, involved side up

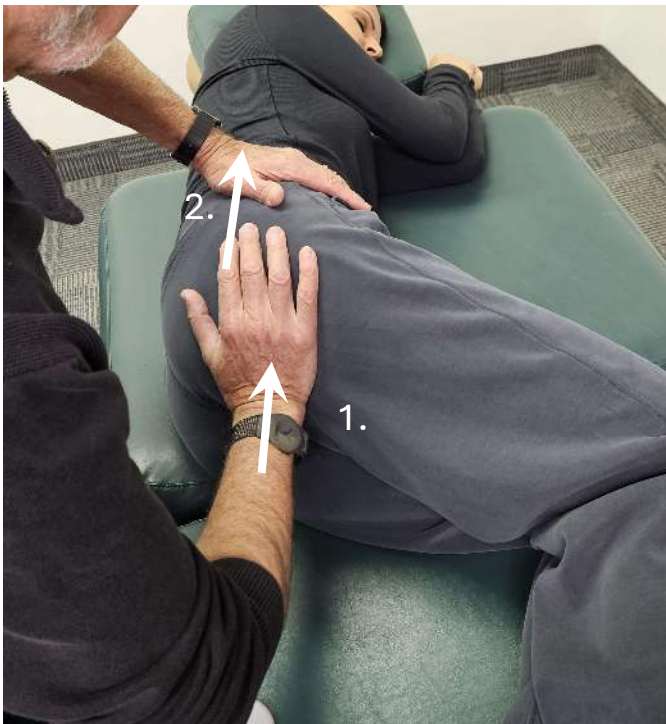Practitioner Position: Side of table, behind patient

Contacts:

1. Superior aspect of iliac crest
2. Superior aspect of greater trochanter

Containment:

1. Inferior
2. Inferior



TREATMENT: -YT

Client Position: Lateral recumbent, involved side up

Practitioner Position: Side of table, behind patient

Contacts:

1. Inferior aspect of ischial tuberosity
2. Lateral aspect of iliac crest

Containment:

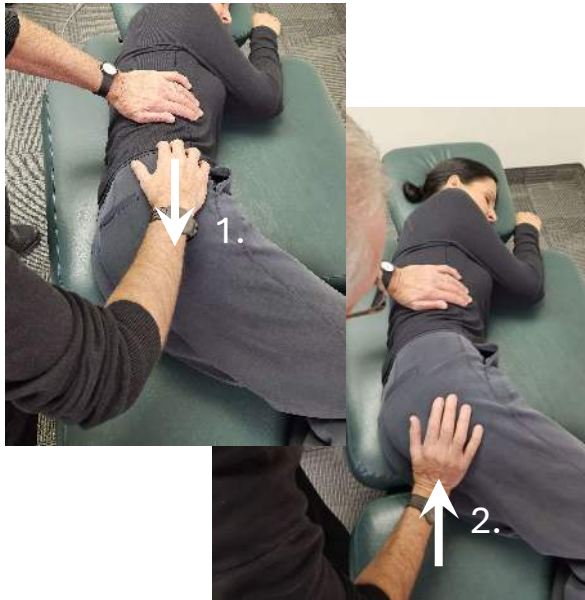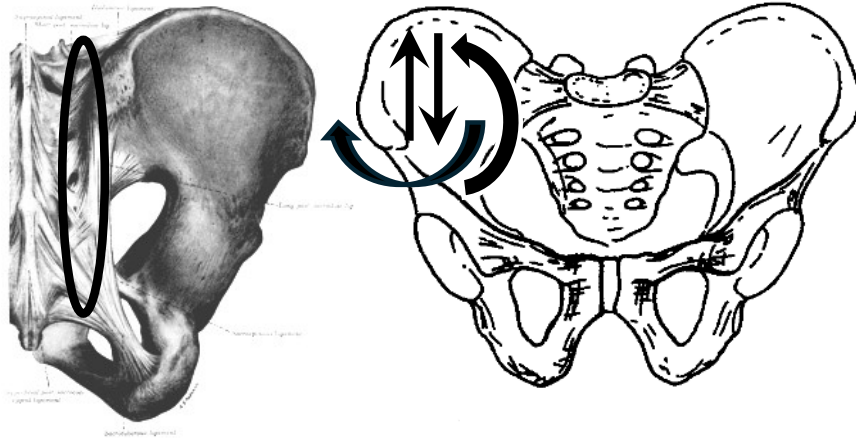
1. Superior
2. Superior

Sacroiliac Joint

LP
SI-YT/
YR/ZR

LESION:

YT +, -, YR -, ZR +
(Y axis translation, positive, negative; Y rotation, positive, negative; ZR positive)



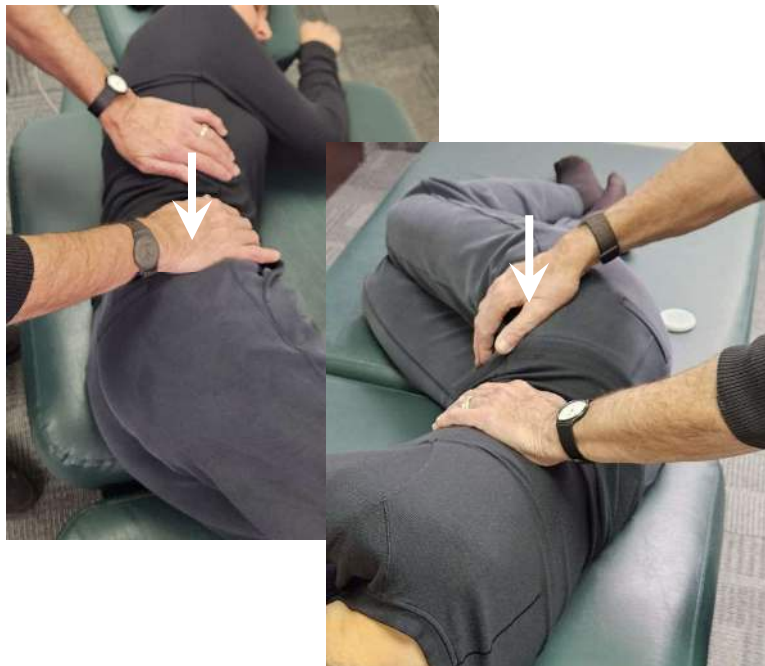TEST: +, - Y Translation

Contact:

1. Superior aspect of ilium
2. Inferior aspect of ischial tuberosity

Containment:

1. Inferior
2. Superior



TEST: +Y Rotation

Contact: Anterior, Medial aspect of ilium

Containment: Medial

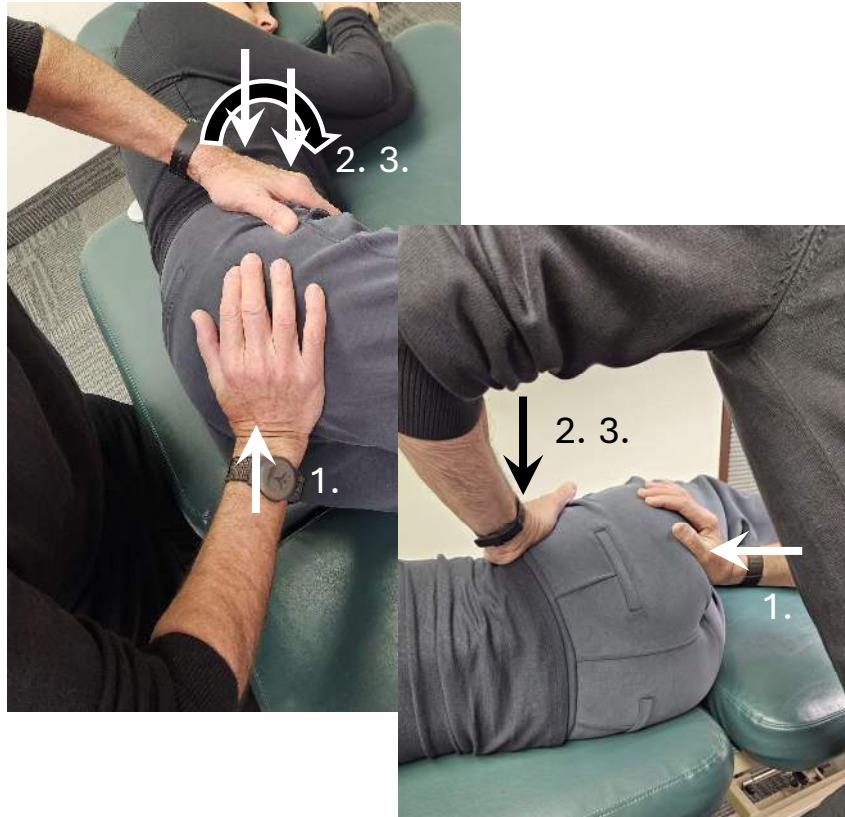TEST: +Z Rotation

Contact: Superior, Lateral aspect of ilium

Containment: Medial

Sacroiliac Joint

LP
**SI-YT/
 YR/ZR**



**TREATMENT: -YT,
 +YR, +ZR**

Client Position:

Lateral recumbent,
 involved side up

Practitioner Position:

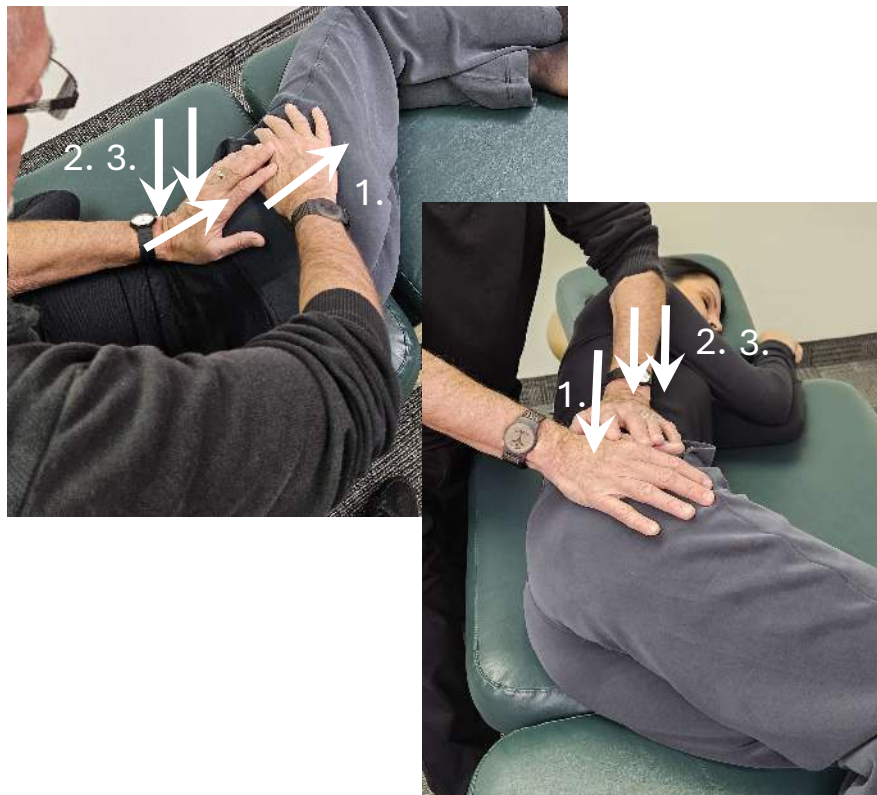
Side of table, behind
 patient

Contacts:

1. Inferior aspect of ischial tuberosity
2. Superior aspect of iliac crest
3. Anterior, superior aspect of iliac crest

Containment:

1. Superior
2. Medial
3. Medial



**TREATMENT: +YT,
 +YR, +ZR**

Client Position:

Lateral recumbent, involved side up

Practitioner Position:

Behind patient, facing
 patient's feet

Contacts:

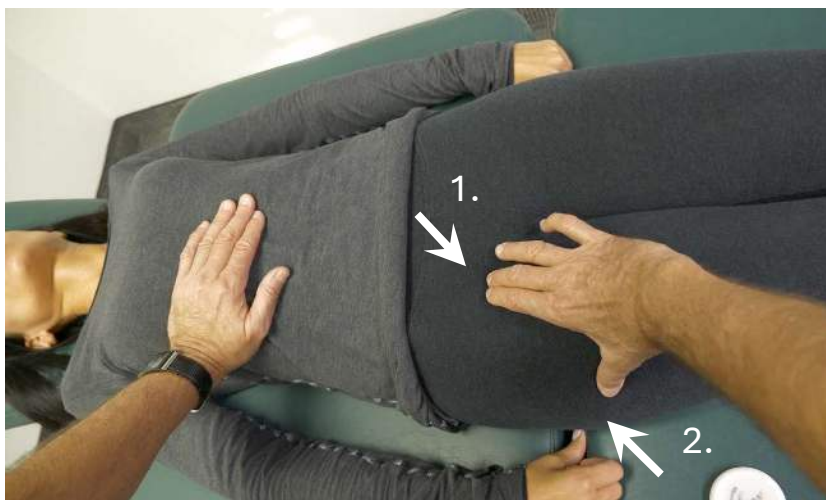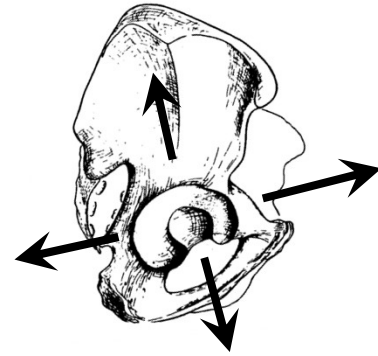
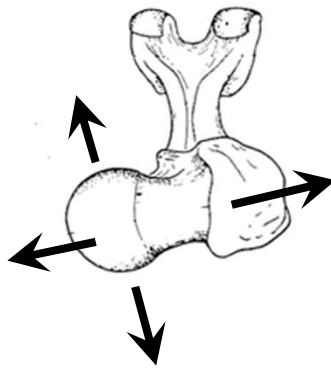
1. Superior aspect of greater trochanter
2. Superior aspect of iliac crest
3. Anterior, superior aspect of iliac crest

Containment:

1. Inferior
2. Inferior, Medial
3. Inferior, Medial

Femoral Head, Neck, and Anterior Acetabulum with hip Internally Rotated

LESIONS: Femoral Head, Neck and Anterior Acetabulum, X / Y / Z Axis Expansion



TEST: X / Y Axis

Contact:

1. Medial aspect of midpoint of inguinal ligament on anterior acetabulum
2. Greater trochanter

Containment:

1. Lateral and inferior
2. Medial and Superior



TEST: Z Axis

Contact: Anterior acetabulum

Containment: Posterior

Femoral Head, Neck, and Anterior Acetabulum with hip Internally Rotated

TREATMENT: X / Y Axis

Client Position: Supine, bolster placed under pelvis at level of posterior acetabulum

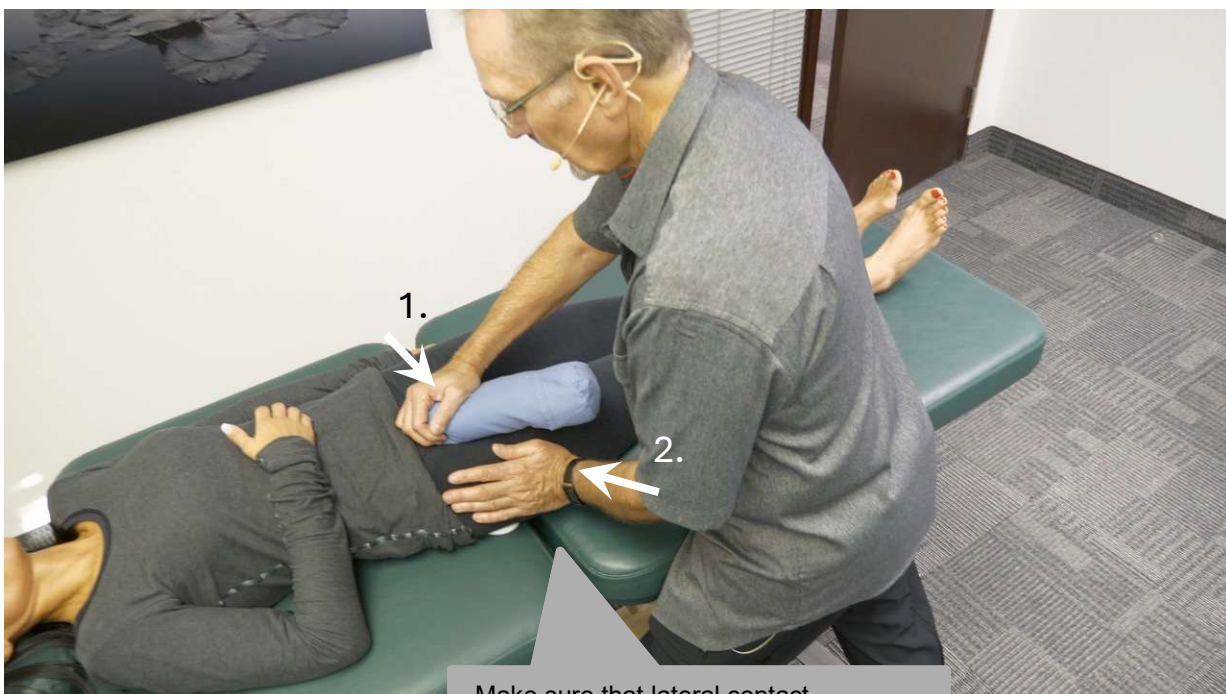
Practitioner Position: Side of table, facing client's head or feet

Contact:

1. Anterior acetabulum
2. Greater trochanter & proximal femur

Containment:

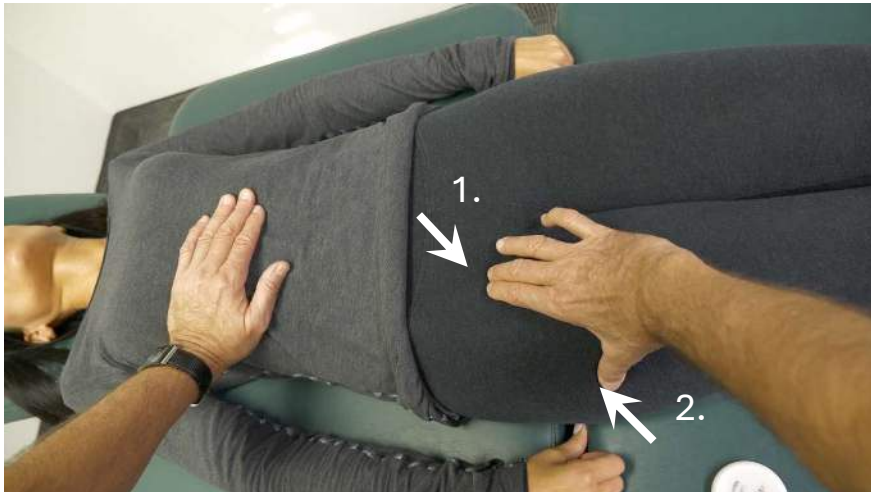
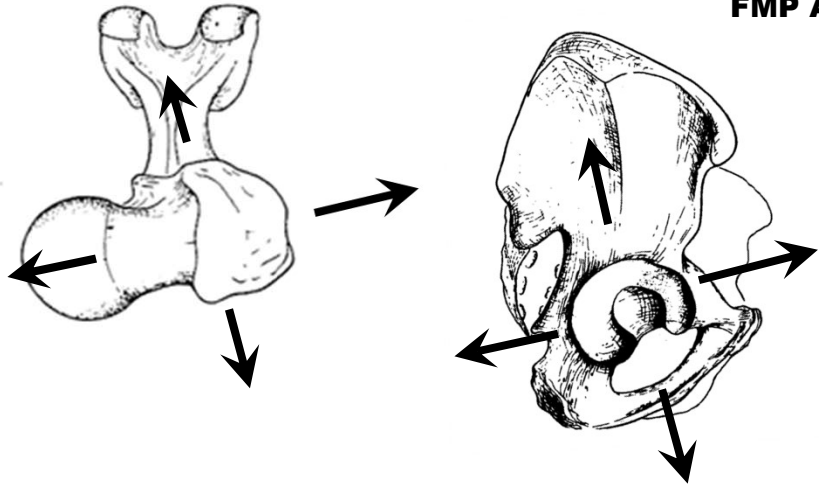
1. Posterior, inferior and lateral
2. Medial and superior



Make sure that lateral contact encompasses the proximal femur as well as the greater trochanter.

Femoral Head, Neck, and Anterior Acetabulum with External Rotation

LESIONS: Femoral Head, Neck and Anterior Acetabulum, X / Y / Z Axis Expansion



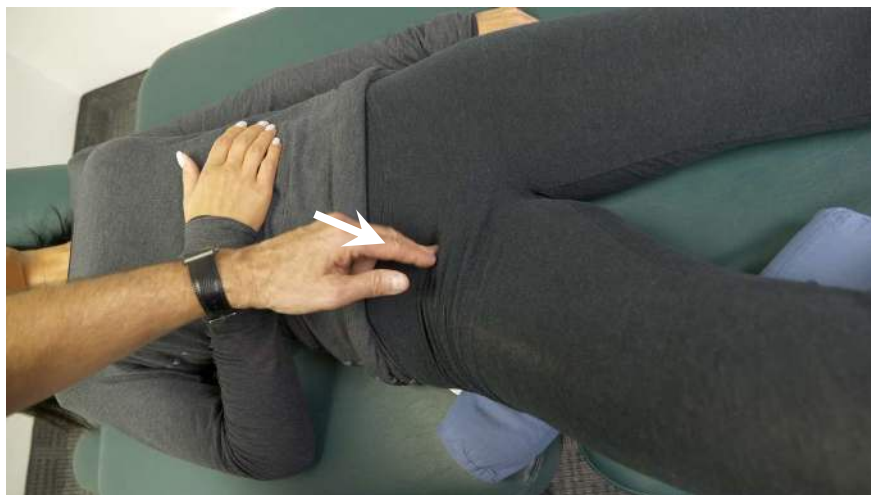TEST: X / Y Axis

Contact:

1. Medial aspect of midpoint of inguinal ligament on anterior acetabulum
2. Greater trochanter

Containment:

1. Lateral and inferior
2. Medial and Superior

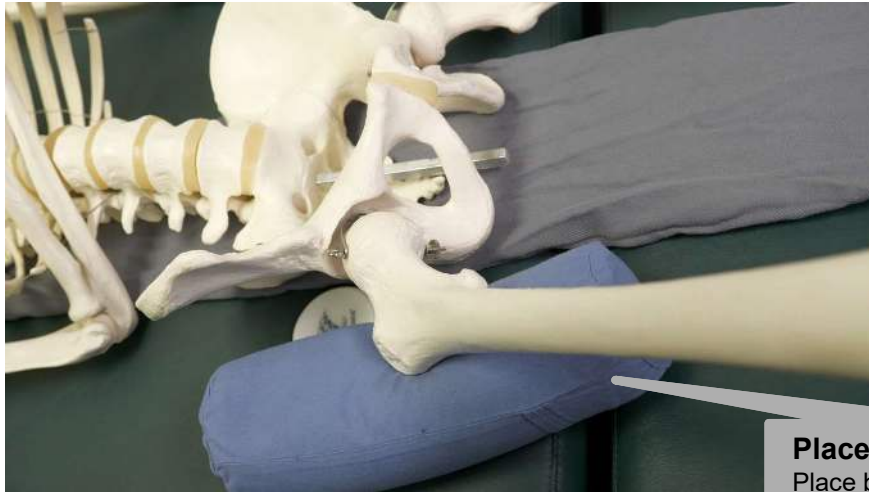

TEST: Z Axis

Contact: Anterior acetabulum with hip externally rotated to approximately 45*

Containment: Posterior, inferior & lateral

Femoral Head, Neck, and Anterior Acetabulum with External Rotation



Place Bolster First

Place bolster at 45 degree angle to the vertical under the greater trochanter.

TREATMENT: Z / Y Axis Combined

Client Position: Supine, bolster supporting greater trochanter

Practitioner Position: Side of table, facing towards client's feet


Contact:

1. Medial aspect of midpoint of inguinal ligament (anterior acetabulum) with hip flexed & externally rotated to approximately 45*
2. Distal head of femur

Containment:

1. Posterior and inferior (optional use of bolster)
2. Superior

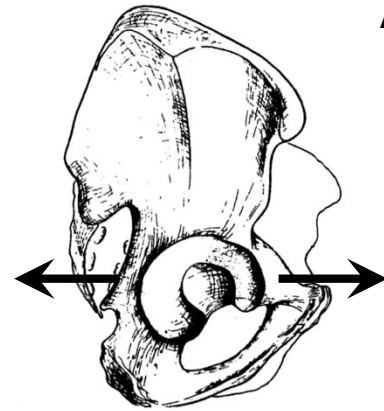
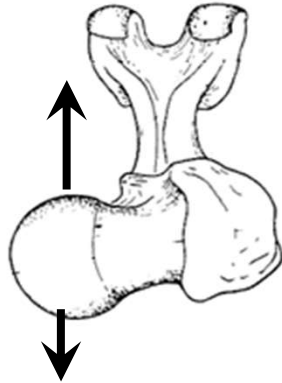
If foot slips out of this position, place a piece of non slip mat under the heel



Femoral Head and Anterior & Posterior Acetabulum **LP**

ACT A-P

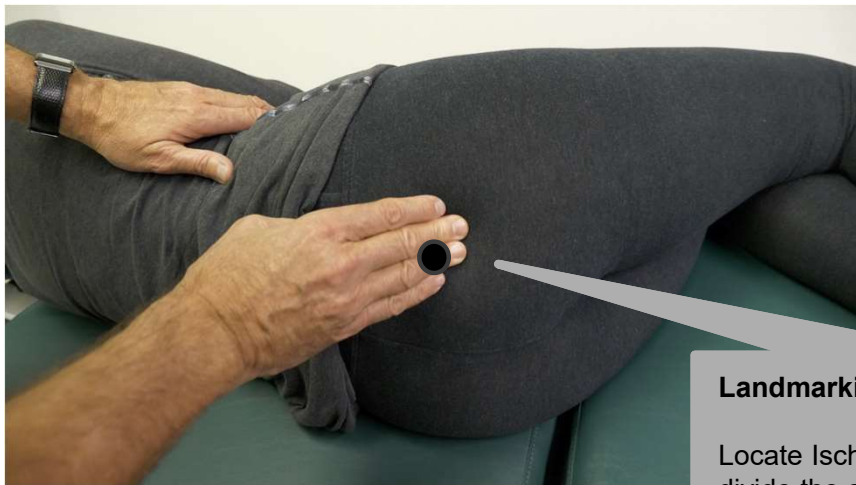LESION: Femoral Head and Anterior & Posterior Acetabulum Z Axis Expansion



TEST: Z Axis

Contact: Anterior acetabulum (medial aspect of midpoint of inguinal ligament)

Containment: Posterior



TEST: Z Axis

Contact: Posterior acetabulum (roughly 4 cm superior from ischial tuberosity)

Containment: Anterior

Landmarking Posterior Acetabulum:

Locate Ischial tuberosity and PSIS. Then divide the area into 3rds in direct line. Middle 3rd represents the area of the posterior acetabulum.

Femoral Head and Anterior & Posterior Acetabulum **LP**

ACT A-P

TREATMENT: Z Axis

Client Position: Lateral recumbent, involved side up

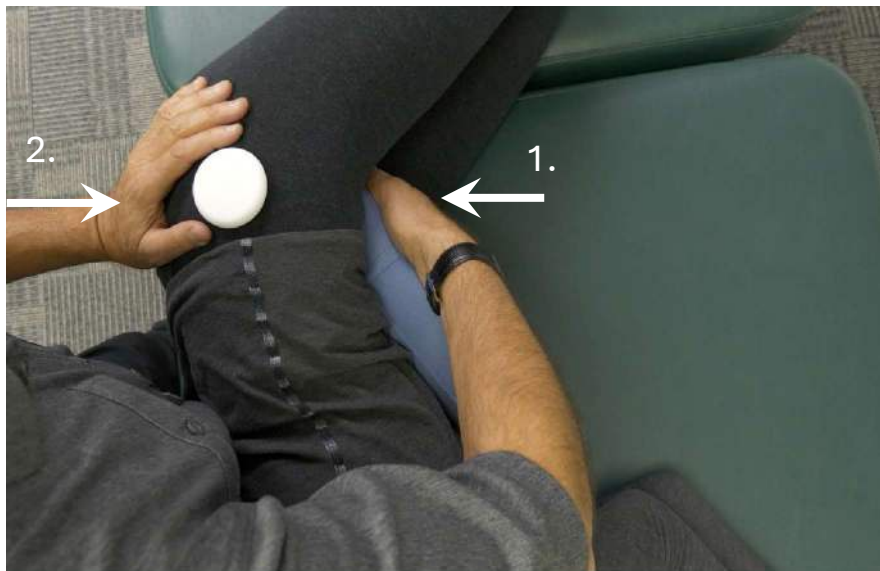Practitioner Position: Side of table, facing towards client's feet

Contact:

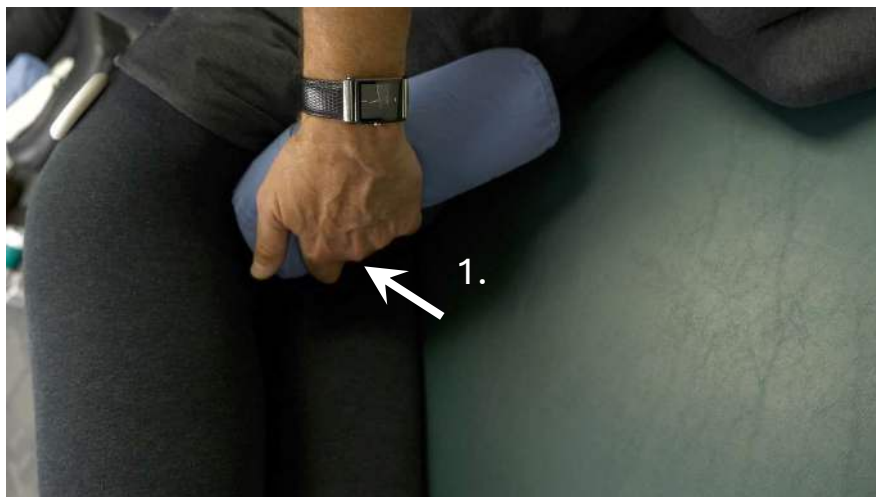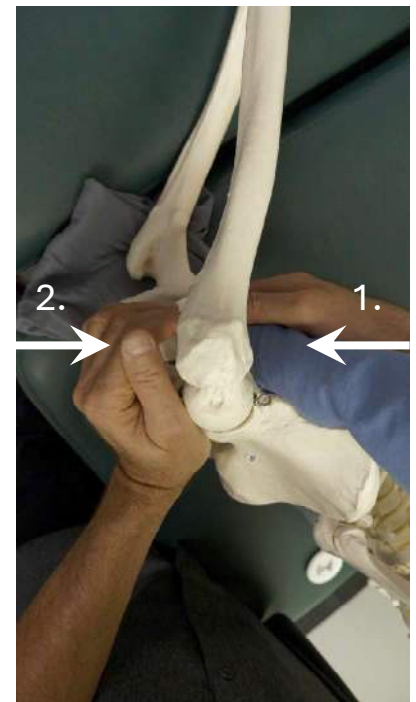
1. Anterior acetabulum (medial aspect of midpoint of inguinal ligament)
2. Posterior acetabulum (roughly 4 cm superior from ischial tuberosity)

Containment:

1. Posterior
2. Anterior

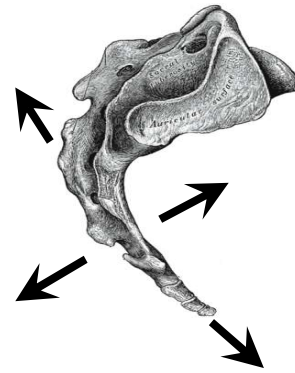
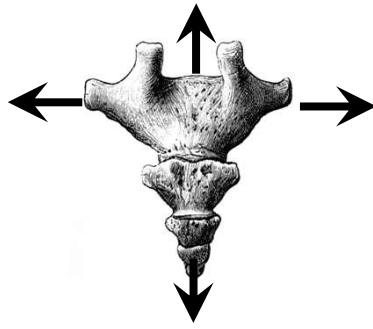


Boney Contact

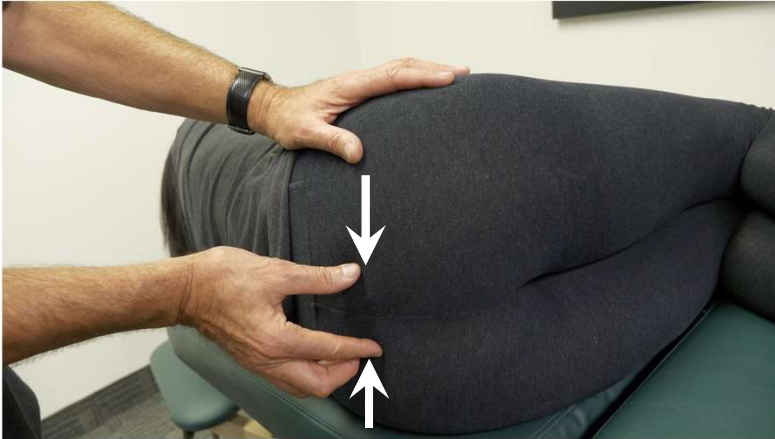

Coccyx

LESION: Coccyx,
X / Y / Z Axis
Expansion



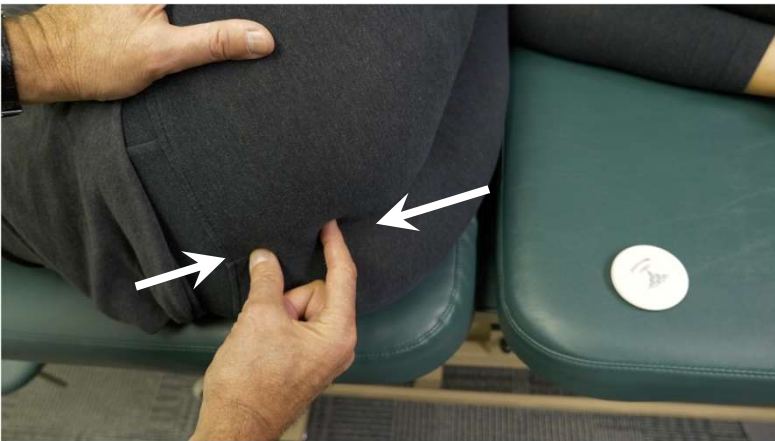LP
COX



TEST: X Axis

Contact: Lateral aspect of coccyx

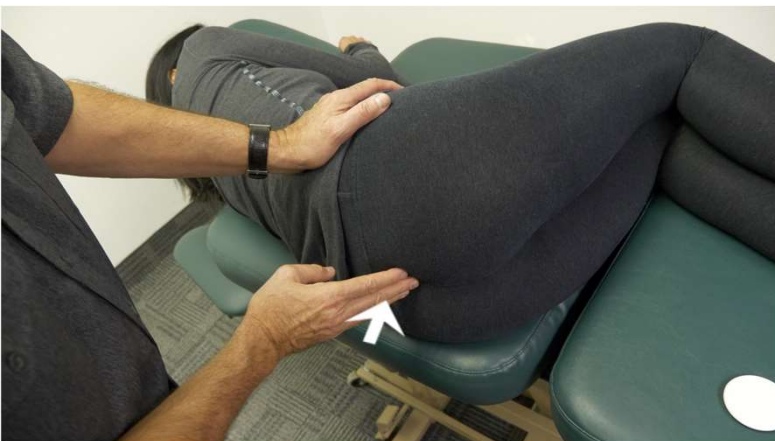Containment: Medial



TEST: Y Axis

Contact: Superior and inferior
coccyx

Containment: Superior and
inferior



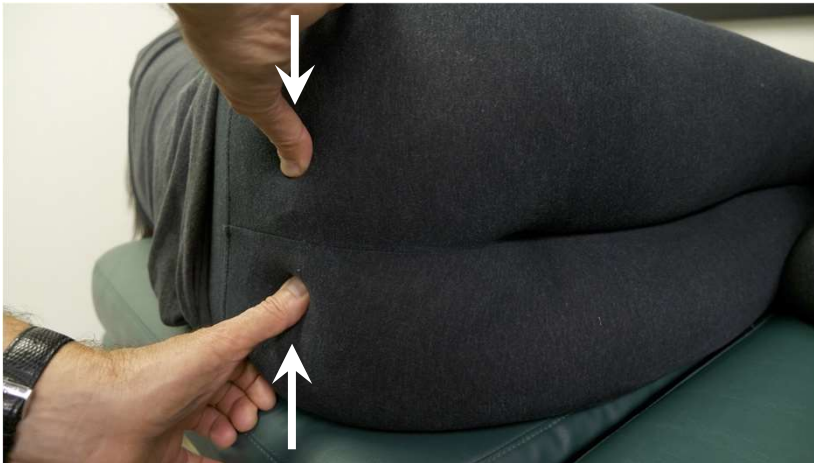
TEST: Z Axis

Contact: Posterior coccyx

Containment: Anterior

Coccyx

LP
COX



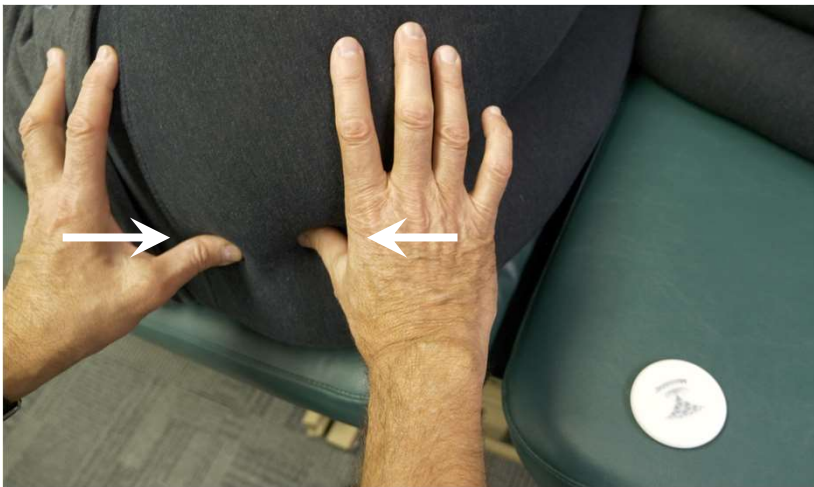TREATMENT: X Axis

Client Position: Prone or lateral recumbent

Practitioner Position: Side of table, facing back of client's body

Contact: Lateral aspects of coccyx

Containment: Median



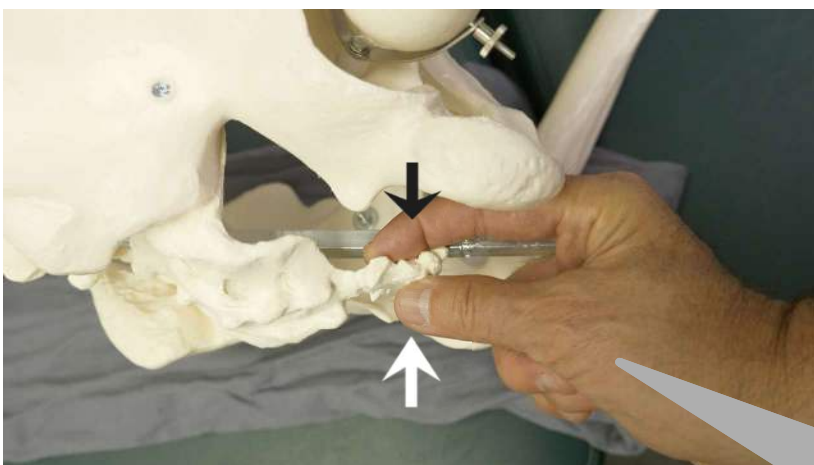
TREATMENT: Y Axis

Client Position: Prone or lateral recumbent

Practitioner Position: Side of table, facing back of client's body

Contact: Superior and inferior aspects of coccyx

Containment: Inferior and superior



TREATMENT: Z Axis

Client Position: Prone or lateral recumbent

Practitioner Position: Side of table, facing back of client's body

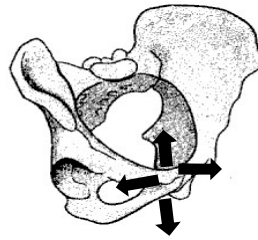
Contact: Posterior and anterior aspects of coccyx

Containment: Anterior and posterior

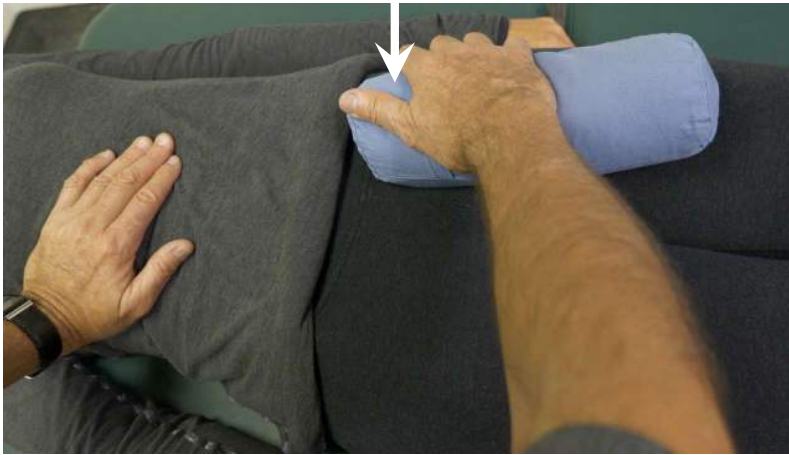
Internal approach to treat the coccyx in the Z Axis may also be indicated. Restricted to practitioners with appropriate licensing.

Pubis

LESION: Pubis, X / Y Axis Expansion



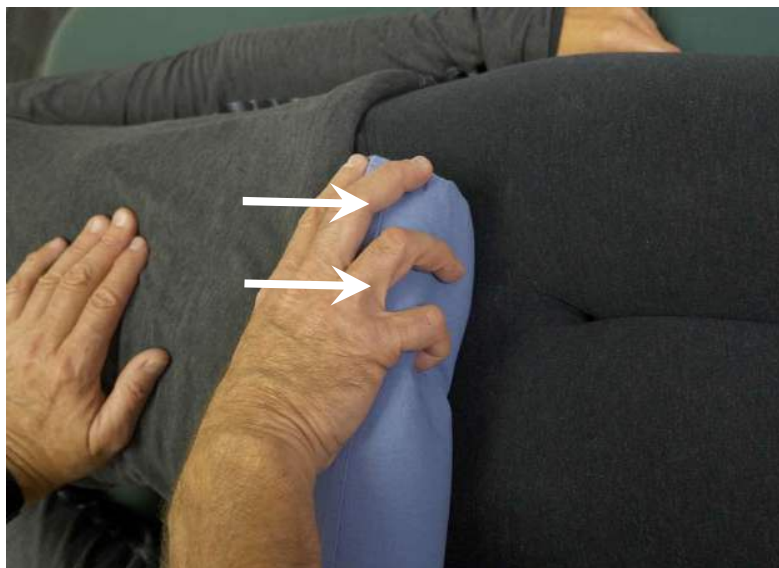

LP
PUB



TEST: X Axis

Contact: Medial & lateral aspects of pubic body

Containment: Medial



TEST: Y Axis

Contact: Superior aspects of pubic body

Containment: Inferior

Pubis

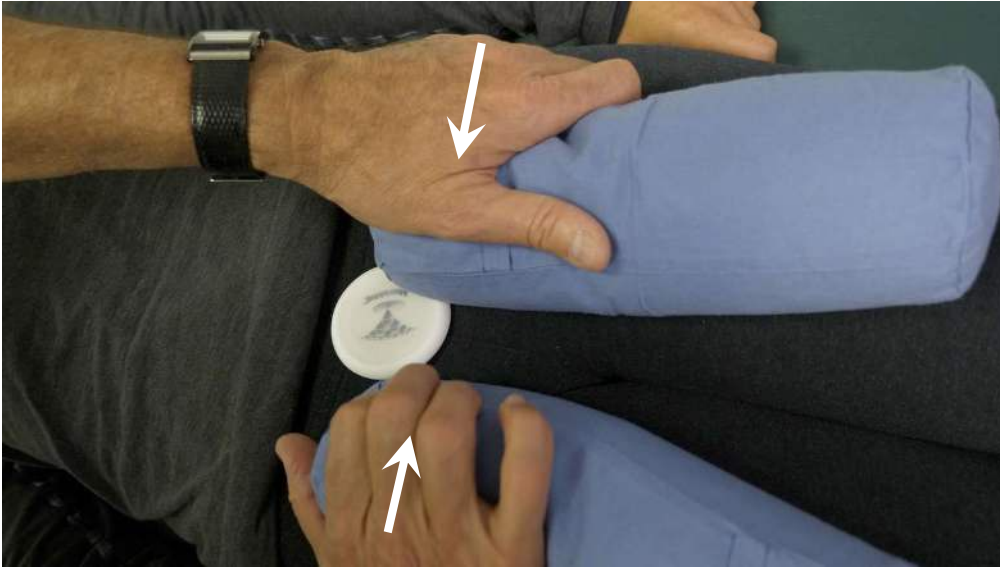
TREATMENT: X Axis

Client Position: Supine

Practitioner Position: Side of table, facing side of client's body

Contact: Lateral aspect of pubic body, bilaterally

Containment: Median



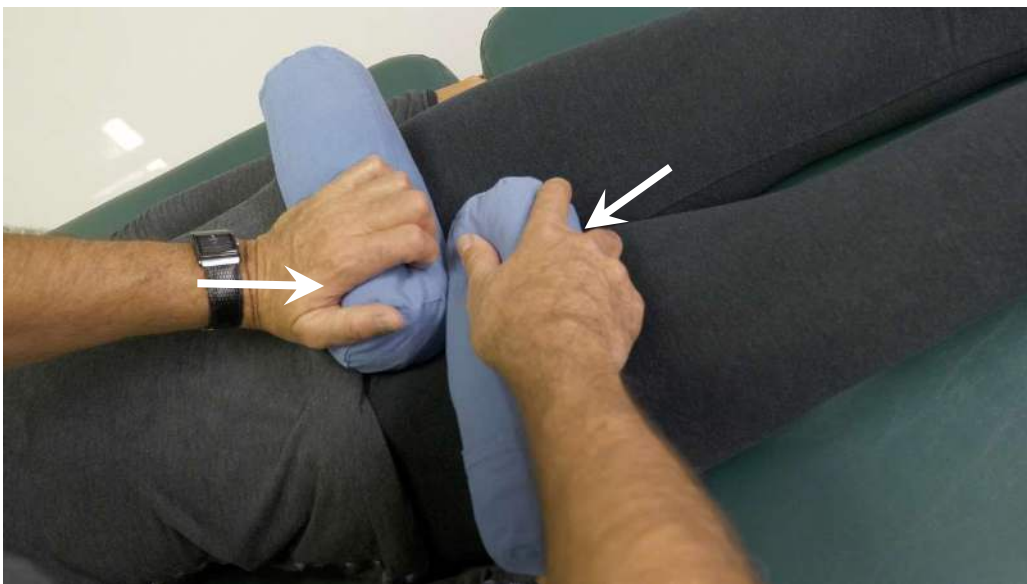TREATMENT: Y Axis

Client Position: Supine

Practitioner Position: Side of table, facing side of client's body

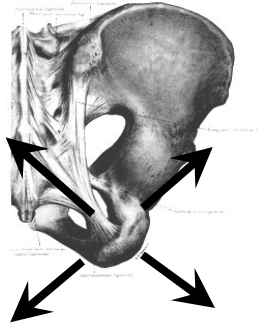
Contact: Superior and inferior aspects of pubic body

Containment: Inferior and superior



Ischial Tuberosity

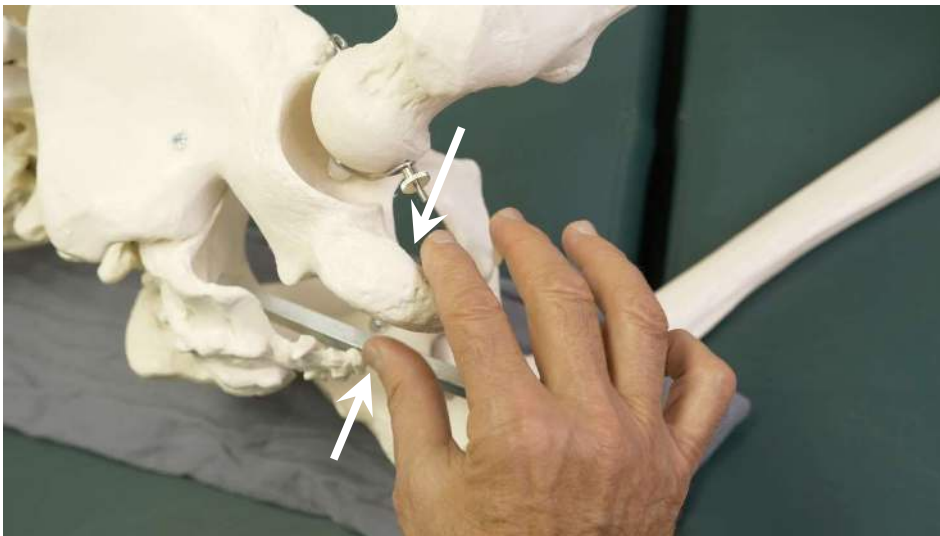LESION: Ischial tuberosity, X / Z Axis Expansion



TEST: X Axis

Contacts: Medial and lateral ischial tuberosity

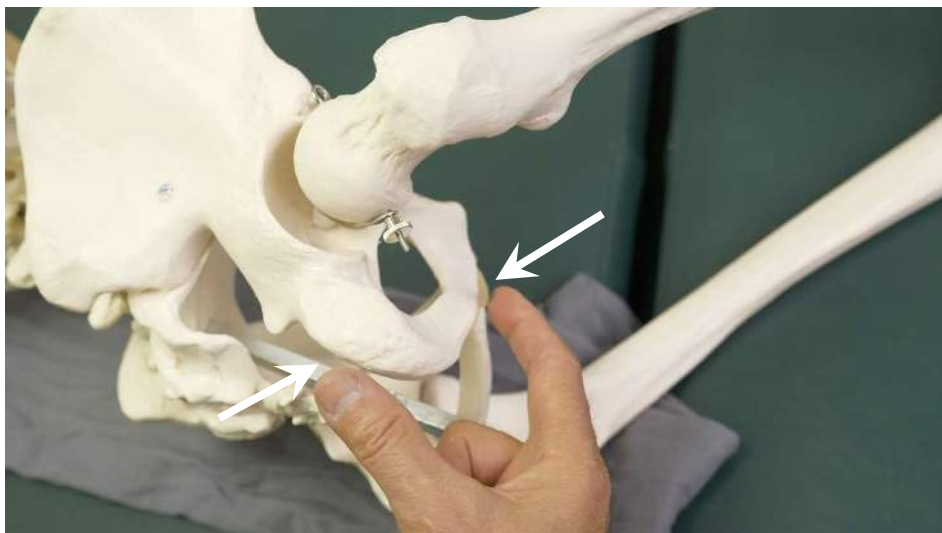
Containment: Lateral and medial



TEST: Z Axis

Contacts: Anterior and posterior ischial tuberosity

Containment: Posterior and anterior



Ischial Tuberosity

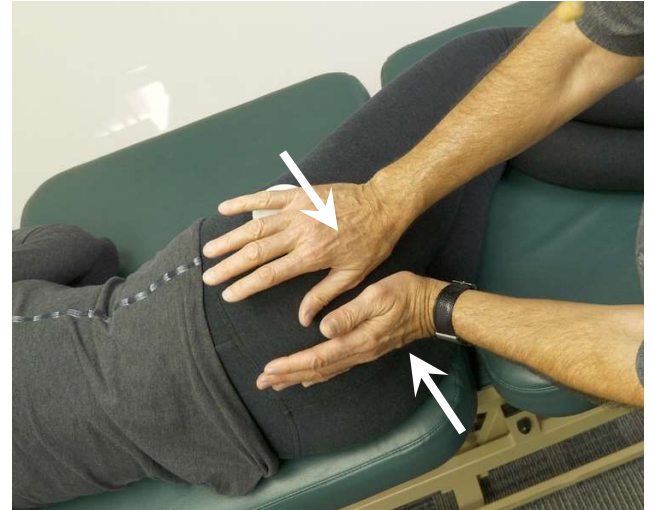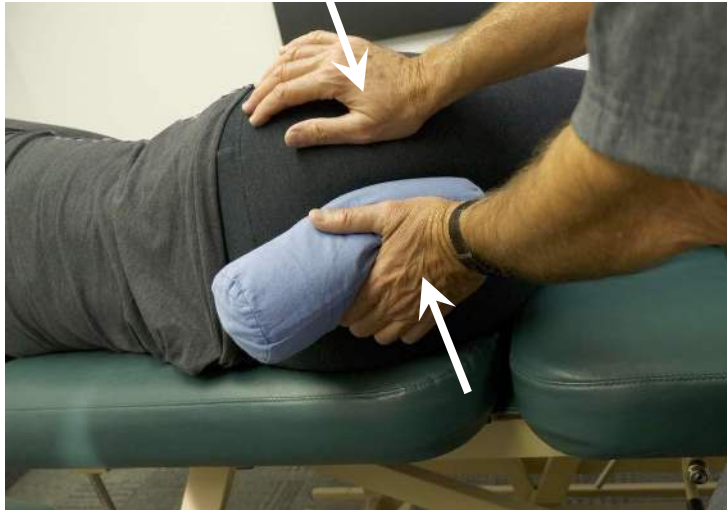TREATMENT: X Axis

Client Position: Lateral recumbent involved side up, knees may be supported by a pillow

Practitioner Position: Side of table, facing client's head

Contacts: Medial & lateral ischial tuberosity

Containment: Lateral and medial (bolster may be used for contact)



TREATMENT: Z Axis

Client Position: Lateral recumbent involved side up, knees may be supported by a pillow

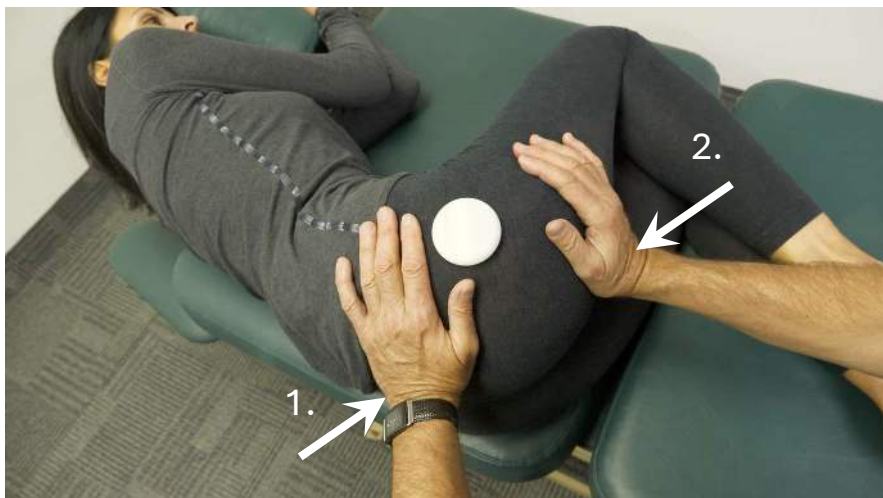Practitioner Position: Side of table facing, client's head

Contacts:

1. Ischial body
2. Inferior ramus of pubis (adjacent to ischial tuberosity)

Containment:

1. Anterior
2. Posterior



Notes